



**PATIENT PRESENTING CLINICAL SIGNS**

Kola Craig Congestion, sneezing, no color to discharge, for several months  
Abnormal PE/Chem/CBC/UA Results: Right nasal discharge

**SPECIES COMPUTED TOMOGRAPHY OF THE SKULL**

Feline A high resolution pre- and post-contrast CT study of the skull is provided for review.

**COMPUTED TOMOGRAPHIC FINDINGS**

The pictured parts of the dentition are complete and unremarkable in all jaw quadrants.

**BREED**

DSH

The ventral aspect of the mid segment of the right nasal cavity, is obliterated by soft tissue attenuating and moderate contrast enhancing material; focal destruction of the nasal conchal structures is seen. The nasal soft tissue material is dissecting through the nasal septum into the left nasal septum. The right frontal sinus contains inspissated soft tissue material. The right maxillary bone in contact with the nasal soft tissue mass presents moth eaten osteolytic lesions.

**SEX**

Neutered Male

Both temporomandibular joints present congruent joint spaces with even subchondral bone surfaces and are considered within normal limits.

**AGE**

8 Years, 10 Months

The right tympanic bulla is filled with soft tissue attenuating and non-contrast enhancing material. The osseous lining of the right tympanic bulla is mildly thickened and smooth. In the left tympanic bulla, a small amount of soft tissue material is attached to the wall. The external ear canals are within normal limits.

**INTERPRETED BY**

Sebastian Schaub, DVM  
Dr. med. vet. DipECVDI

The brain presents no deviation from normal anatomy and symmetry. The brain parenchyma is homogeneous and within normal limits for attenuation and distribution of contrast enhancement. The ventricular system is non-dilated and symmetric.

**HOSPITAL NAME**

Mobile Pet Imaging

The submandibular and medial retropharyngeal lymph nodes are small and elongated with a normal short-to-long-axis-ratio is < 0.5, the attenuation and contrast enhancement pattern is uniform.

**COMPUTED TOMOGRAPHIC DIAGNOSIS**

- Contrast enhancing nasal soft tissue mass perforating the nasal septum
- Right sided otitis media

**REFERRING VET**

Meaux

**INTERPRETATION OF THE FINDINGS & FURTHER RECOMMENDATIONS**

The nasal soft tissue material is highly concerning for primary nasal neoplasia, such as lymphosarcoma, adenocarcinoma, squamous cell carcinoma, transitional cell carcinoma, other. Differentials can include nasal granuloma or inflammatory pseudotumor. Rhinoscopy including biopsy would be ideal as advanced diagnostic tests.

**INVOICE**

57684

**DATE**

4-6-23



**PATIENT**

Kola Craig

**SPECIES**

Feline

**BREED**

DSH

**SEX**

Neutered Male

**AGE**

8 Years, 10 Months

**INTERPRETED BY**

Sebastian Schaub, DVM  
Dr. med. vet. DipECVDI

**HOSPITAL NAME**

Mobile Pet Imaging

**REFERRING VET**

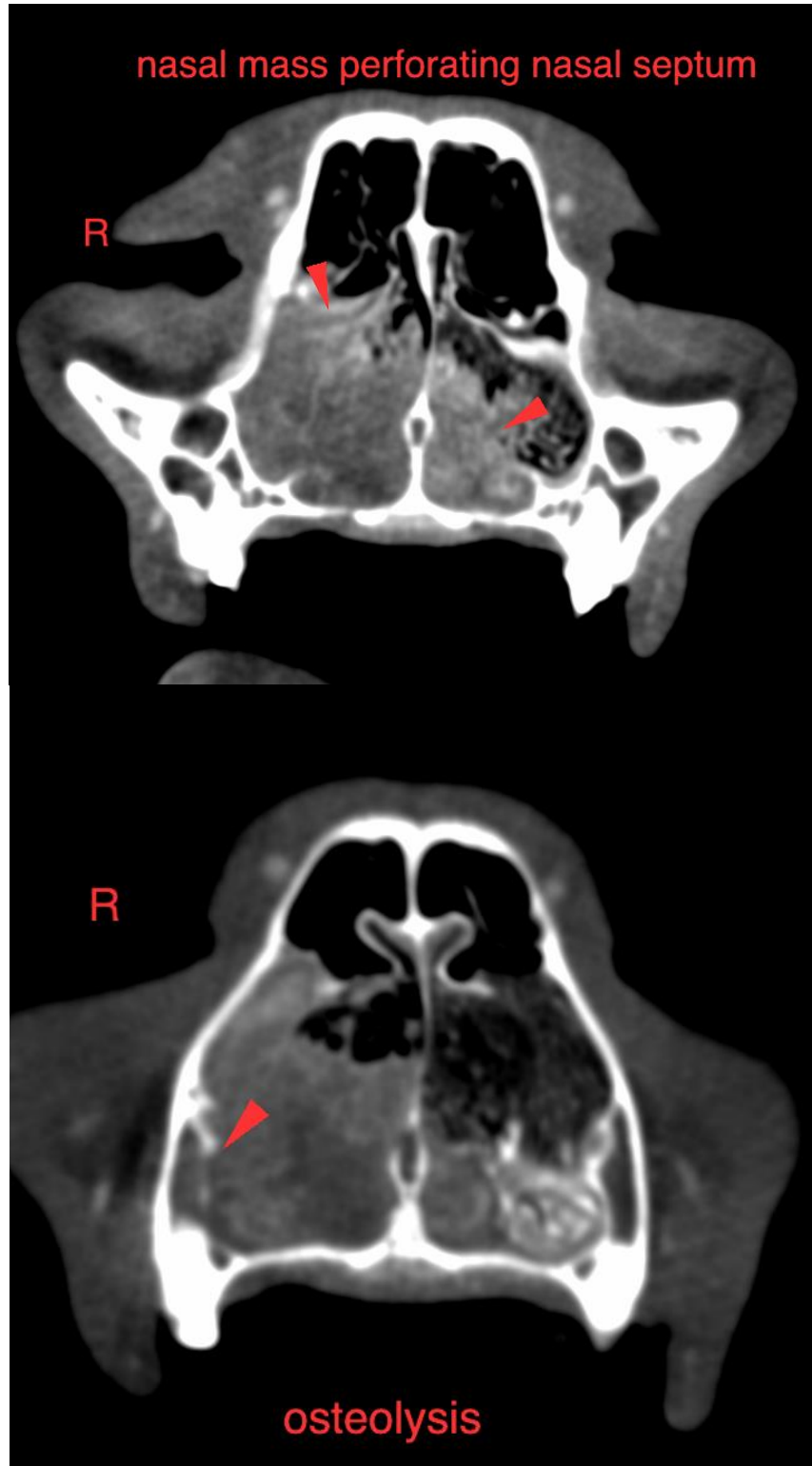
Meaux

**INVOICE**

57684

**DATE**

4-6-23





**PATIENT**

Kola Craig

**SPECIES**

Feline

The information and recommendations provided are based on the images presented by the referring veterinarian/sonographer. No evaluation can be communicated regarding pathology that was not visible in the image/video clips provided.

**BREED**

DSH

Thank you for this referral. If the clinical or image interpretation does not parallel your findings or if I can be of any further assistance please contact me.

**SEX**

Neutered Male

**Sebastian Schaub**, Sebastian Schaub, DVM, Dr. med. vet. DipECVDI  
sebast.schaub@gmail.com

**AGE**

8 Years, 10 Months

**INTERPRETED BY**

Sebastian Schaub, DVM  
Dr. med. vet. DipECVDI

**HOSPITAL NAME**

Mobile Pet Imaging

**REFERRING VET**

Meaux

**INVOICE**

57684

**DATE**

4-6-23