



PATIENT PRESENTING CLINICAL SIGNS

Teddy Blekman History: Intermittent neck pain, yelping when flexed ventrally
Abnormal PE/Chem/CBC/UA Results:

SPECIES RADIOGRAPHIC STUDY OF THE CERVICAL SPINE

Canine A lateral projection of the cervical spine is provided for review.

RADIOGRAPHIC FINDINGS

BREED

Standard Poodle The vertebral bodies and the lamina of C2/C3 are fused. The remainder of the osseous structures of the cervical spine are within normal limits and the surrounding soft tissue structures present without abnormalities.

SEX RADIOGRAPHIC DIAGNOSIS

Spayed Female

- Block vertebra C2/C3

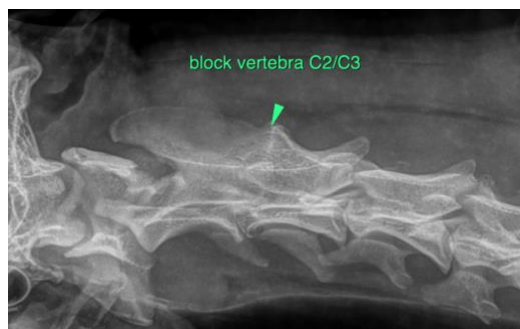
INTERPRETATION OF THE FINDINGS & FURTHER RECOMMENDATIONS

AGE

8 Years The block vertebra C2/C3 can cause increased load on the adjacent intervertebral disc spaces, potentially predisposing for discopathy. If there is strong suspicion for compressive myelopathy of the cervical spine, recommend complementing workup by CT or MRI study.

INTERPRETED BY

Sebastian Schaub,
DVM Dr. med. vet.
DipECVDI



HOSPITAL NAME

New Bridge VP

REFERRING VET

Dr. Abina Glennon

The information and recommendations provided are based on the images presented by the referring veterinarian/sonographer. No evaluation can be communicated regarding pathology that was not visible in the image/video clips provided.

INVOICE

14626

Thank you for this referral. If the clinical or image interpretation does not parallel your findings or if I can be of any further assistance please contact me.

Sebastian Schaub, Sebastian Schaub, DVM, Dr. med. vet. DipECVDI
sebast.schaub@gmail.com

DATE

4/6/22



PATIENT

Teddy Blekman

SPECIES

Canine

BREED

Standard Poodle

SEX

Spayed Female

AGE

8 Years

INTERPRETED BY

Sebastian Schaub,
DVM Dr. med. vet.
DipECVDI

HOSPITAL NAME

New Bridge VP

REFERRING VET

Dr. Abina Glennon

INVOICE

14626

DATE

4/6/22