

**PATIENT PRESENTING CLINICAL SIGNS**

Luna Yarbrough History: history of chronic (off and on for about a year) lameness of the front left limb  
Abnormal PE/Chem/CBC/UA Results:

**SPECIES COMPUTED TOMOGRAPHIC STUDY OF THE FRONT LIMBS**

Canine A high resolution pre- and post-contrast CT study of the front limbs is provided for review.

**COMPUTED TOMOGRAPHIC FINDINGS**

**BREED**  
Border Collie Mix  
**SEX**  
Spayed Female

The periarticular bones of both elbow joints present mild to moderate osteophyte new bone formation. The tip of the medial coronoid process of the left elbow joint presents a moderate decreased and mildly heterogeneous density and is irregular marginated; there is an ill-defined fissure line in the middle segment of the medial coronoid process. The tip of the medial coronoid process of the right elbow joint is mildly irregular. The joint space of both elbow joints is congruent. Level with the joint capsule, at the medial aspect of the right medial humeral condyle, a well-defined roundish mineralized body measuring 2.1 mm in size is seen.

**COMPUTED TOMOGRAPHIC DIAGNOSIS**

- AGE**  
3 Years
- Coronoid disease elbow joints bilaterally, L>R
  - Mild degenerative osteoarthritis elbow joints bilaterally
  - Synovial osteochondromatosis versus metaplasia medial aspect right elbow joint
  - Structural normal shoulder joints

**INTERPRETED BY**

Sebastian Schaub,  
DVM Dr. med. vet.  
DipECVDI

**INTERPRETATION OF THE FINDINGS & FURTHER RECOMMENDATIONS**

The findings are consistent with mild chronic degenerative joint disease of both elbow joints due to pathology of the medial coronoid process.

**HOSPITAL NAME**

Parrish Creek VC

Arthroscopy/arthrotomy would be beneficial to revise at least the clinically relevant left elbow joint and remove the non-vital tip/fragment of the medial coronoid process and prevent further damage.

**REFERRING VET**

Dr. Will Becker

**INVOICE**

14625

**DATE**

4/6/22



**PATIENT**

Luna Yarbrough

**SPECIES**

Canine

**BREED**

Border Collie Mix

**SEX**

Spayed Female

**AGE**

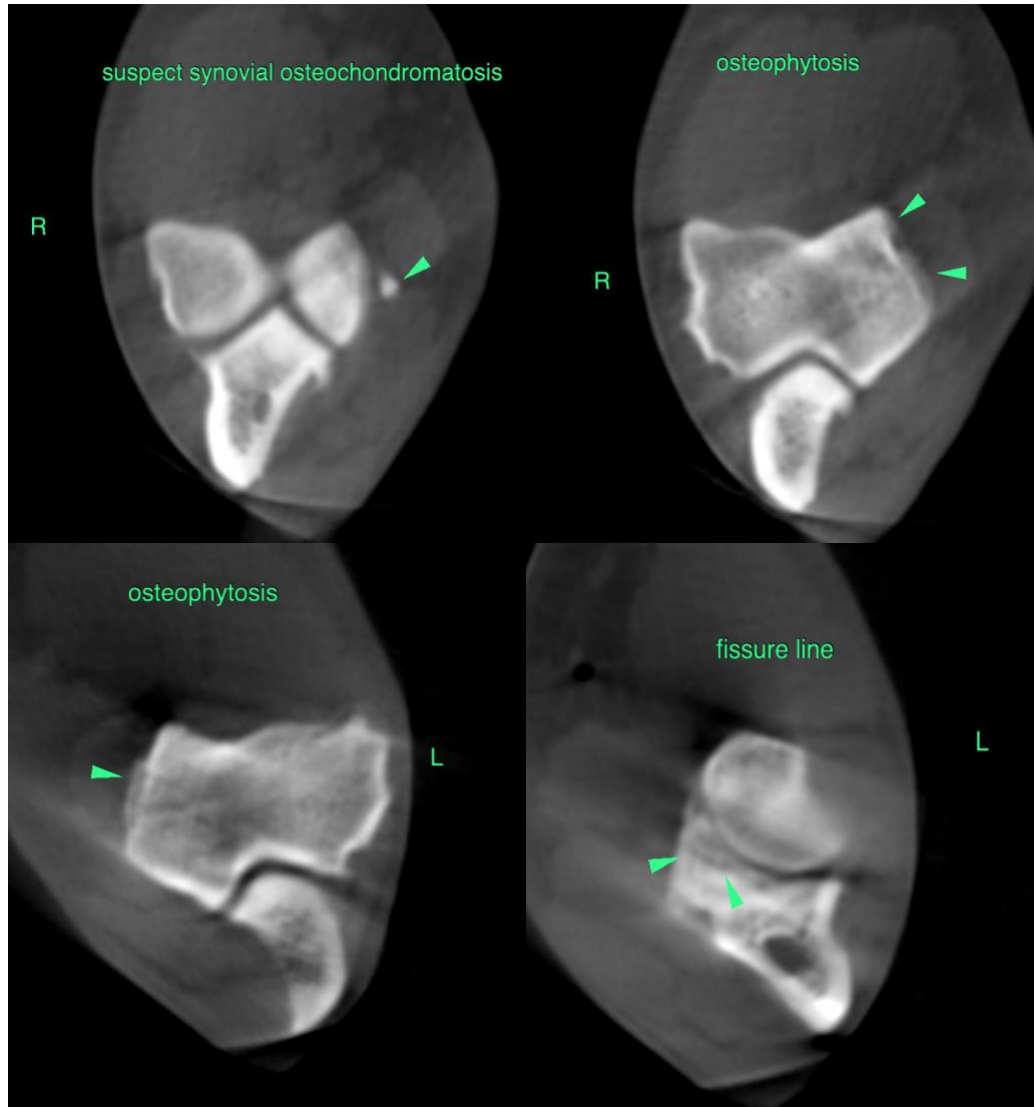
3 Years

**INTERPRETED BY**

Sebastian Schaub,  
DVM Dr. med. vet.  
DipECVDI

**HOSPITAL NAME**

Parrish Creek VC



**REFERRING VET**

Dr. Will Becker

**The information and recommendations provided are based on the images presented by the referring veterinarian/sonographer. No evaluation can be communicated regarding pathology that was not visible in the image/video clips provided.**

Thank you for this referral. If the clinical or image interpretation does not parallel your findings or if I can be of any further assistance please contact me.

**INVOICE**

14625

**Sebastian Schaub**, Sebastian Schaub, DVM, Dr. med. vet. DipECVDI  
sebast.schaub@gmail.com

**DATE**

4/6/22



**PATIENT**

Luna Yarbrough

**SPECIES**

Canine

**BREED**

Border Collie Mix

**SEX**

Spayed Female

**AGE**

3 Years

**INTERPRETED BY**

Sebastian Schaub,  
DVM Dr. med. vet.  
DipECVDI

**HOSPITAL NAME**

Parrish Creek VC

**REFERRING VET**

Dr. Will Becker

**INVOICE**

14625

**DATE**

4/6/22