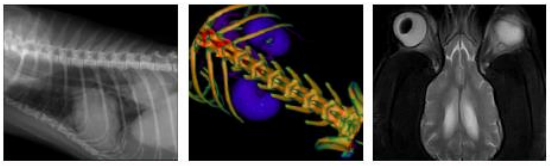

SonoPath.com
1-800-838-4268 info@sonopath.com

PATIENT

Lemon Marshall

SPECIES

Feline

BREED

DSH

SEX

Spayed Female

AGE

6 Years

INTERPRETED BY

Sebastian Schaub, DVM Dr. med. vet. DipECVDI

HOSPITAL NAME

Animal Health Partners

REFERRING VET

Dr. Lea Mehrkens

INVOICE

14614

DATE

4/6/22

PRESENTING CLINICAL SIGNS

History: possible right ear polyp. Lemon has dark brown discharge and liquid from ear canal. Lemon also shakes her head often. Lemon has had otitis external of her right ear since adoption (Fall 2021). OTE was treated with Osurnia (florfenicol, terbinafine, betamethasone acetate) and Rt. ear polyp was suspected during the recheck in December.

COMPUTED TOMOGRAPHIC STUDY OF THE SKULL

A high resolution pre- and post-contrast CT study of the skull is provided for review.

COMPUTED TOMOGRAPHIC FINDINGS

All teeth but triadan 101-103, 201, 202, 303, 304, 402-404 are absent. Fragments of the roots of triadan 104, 106 107, 108, 109, 204, 207, 208, 209, 307-309, 407-409 are seen in their respective alveolar crests without signs of pathological widening of the periodontal space.

The nasal cavity presents the expected aerated spaces between thin & even conchae and turbinates with smooth mucosal lining.

Both temporomandibular joints present congruent joint spaces with even subchondral bone surfaces and are considered within normal limits.

Both tympanic bullae are filled with non-contrast enhancing soft tissue material. The osseous lining of both tympanic bullae is moderately thickened and smooth. The osseous segment of the Eustachian tube bilaterally is moderately widened and contains a small amount of gas and soft tissue attenuating material. The left external ear canal presents mild irregular epithelial lining. The horizontal segment of the right external ear canal is occupied by heterogeneous peripheral accentuated soft tissue material.
The brain presents no deviation from normal anatomy and symmetry. The brain parenchyma is homogeneous and within normal limits for attenuation and distribution of contrast enhancement. The ventricular system is non-dilated and symmetric.

The submandibular and medial retropharyngeal lymph nodes are small and elongated with a normal short-to-long-axis-ratio is < 0.5, the attenuation and contrast enhancement pattern is uniform.

COMPUTED TOMOGRAPHIC DIAGNOSIS

- Bilateral chronic otitis media with widening of the Eustachian tube
- Contrast enhancing material extending into right external ear canal
- Evidence of left sided mild otitis externa
- Multiple absent teeth with retained roots in the alveolar bone, without signs of abscess/granuloma formation

INTERPRETATION OF THE FINDINGS & FURTHER RECOMMENDATIONS

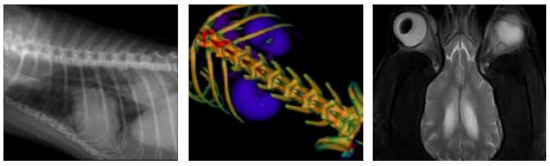

SonoPath.com
1-800-838-4268 info@sonopath.com

PATIENT

Lemon Marshall

SPECIES

Feline

BREED

DSH

SEX

Spayed Female

AGE

6 Years

INTERPRETED BY

Sebastian Schaub, DVM Dr. med. vet. DipECVDI

HOSPITAL NAME

Animal Health Partners

REFERRING VET

Dr. Lea Mehrkens

INVOICE

14614

DATE

4/6/22

The CT study is supporting the diagnosis of an inflammatory polyp extending into the right external ear canal, the base of the polyp can be level with the tympanic membrane or is originating from the epithelial lining of the right external ear canal. Removal of the polyp by traction technique appears as a feasible option, including sampling for histopathology to rule out malignant transformation.
The chronic otitis media can be a trigger for polyp formation and the widened Eustachian tubes might be a sequela to preceding polyps with secondary pressure atrophy. Both conservative management of the otitis media or surgical options can be discussed with dermatology/surgeon.

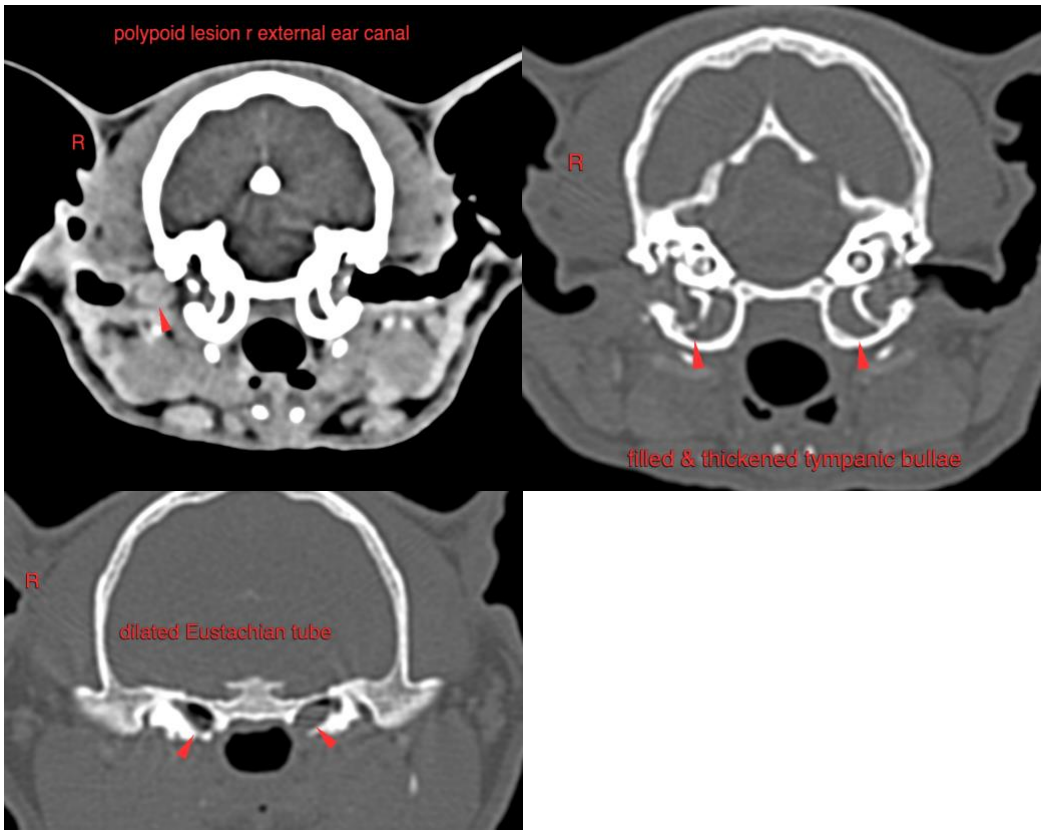

The information and recommendations provided are based on the images presented by the referring veterinarian/sonographer. No evaluation can be communicated regarding pathology that was not visible in the image/video clips provided.

Thank you for this referral. If the clinical or image interpretation does not parallel your findings or if I can be of any further assistance please contact me.

Sebastian Schaub, Sebastian Schaub, DVM, Dr. med. vet. DipECVDI
sebast.schaub@gmail.com

SonoPath Teleradiology

EDUCATIONAL TELECONSULTATION SERVICES™

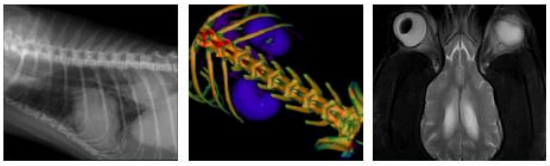

SonoPath.com

1-800-838-4268 info@sonopath.com

PATIENT

Lemon Marshall

SPECIES

Feline

BREED

DSH

SEX

Spayed Female

AGE

6 Years

INTERPRETED BY

Sebastian Schaub, DVM Dr. med. vet. DipECVDI

HOSPITAL NAME

Animal Health Partners

REFERRING VET

Dr. Lea Mehrkens

INVOICE

14614

DATE

4/6/22