



**PATIENT PRESENTING CLINICAL SIGNS**

**Bowie Magder** History: Bowie was presented with a history of one week diarrhea and anorexia. She also had one episode of vomiting after the owner hand fed her today. On the physical exam everything was normal part from being a bit tender on the abdominal palpation. Problem list: - Inflamed rectal MM  
**SPECIES** - Anorexia for a week - Vomiting - Diarrhea - Weight loss  
 Abnormal PE/Chem/CBC/UA Results:

Canine

**RADIOGRAPHIC STUDY OF THE ABDOMEN**

**BREED** Radiographs of the abdomen in three imaging planes are provided for review.

**Shar Pei RADIOGRAPHIC FINDINGS**

**SEX**

Mineralized material is superimposed on the ventral aspect of the neuroforamen L4/L5 and L6/L7.

Spayed Female

No abnormalities of the extraabdominal soft tissues are noted. The abdominal wall is smooth and thin.

**AGE**

The serosal detail is maintained throughout the peritoneal and retroperitoneal space.

3 Years

The liver is appropriate in position, size and presents uniform opacity.

**INTERPRETED BY**

The splenic head is in the anticipated position and within normal limits for size and opacity. The splenic body and tail are considered normal for position, size, shape and opacity.

Sebastian Schaub,  
DVM Dr. med. vet.  
DipECVDI

Both kidneys are seen and present with normal size, shape, delineation and opacity. The urinary bladder is in its anticipated position. No radiopaque calculi are noted throughout the upper and lower urinary tract.

**HOSPITAL NAME**

The stomach is in its anticipated position and contains a mild amount of fluid and gas.

Beaches-Fallingbrook  
VC

The small intestinal loops are generalized mild to moderately distended by gas and fluid and appear adynamic.

The colon is seen in the expected position and is empty but a moderate amount of gas.

**REFERRING VET**

**RADIOGRAPHIC DIAGNOSIS**

Dr. Matt Haghighat

- Empty gastrointestinal tract with adynamic appears small intestinal loops
- Suspect discopathy L4/L5 and L6/L7

**INVOICE**

14628

**INTERPRETATION OF THE FINDINGS & FURTHER RECOMMENDATIONS**

The radiographic changes are suggestive for underlying enteritis/gastroenteritis. There is no evidence of radiopaque foreign material or signs for gastrointestinal mechanical obstruction. If clinical signs

**DATE**

4/6/22



**PATIENT** are refractory to therapy, recommend follow up radiographs or a complete abdominal ultrasound examination; in some cases, a high ileus may lack classical radiographic signs of mechanical obstruction.

Bowie Magder

**SPECIES**

Canine

**BREED**

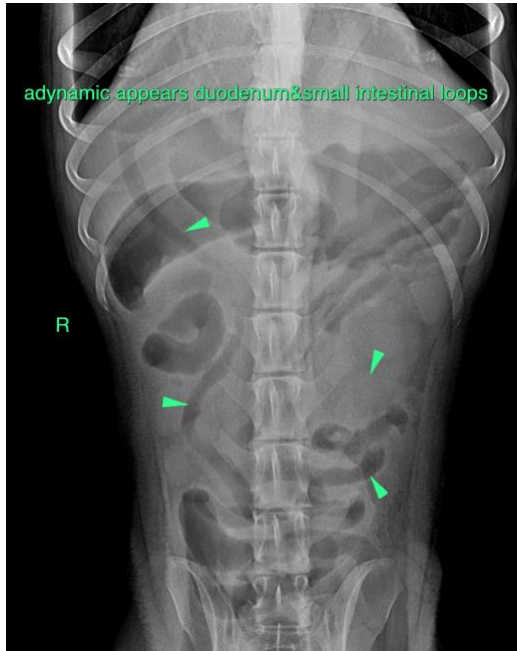
Shar Pei

**SEX**

Spayed Female

**AGE**

3 Years



**INTERPRETED BY**

Sebastian Schaub,  
DVM Dr. med. vet.  
DipECVDI

**The information and recommendations provided are based on the images presented by the referring veterinarian/sonographer. No evaluation can be communicated regarding pathology that was not visible in the image/video clips provided.**

**HOSPITAL NAME**

Beaches-Fallingbrook  
VC

Thank you for this referral. If the clinical or image interpretation does not parallel your findings or if I can be of any further assistance please contact me.

**Sebastian Schaub**, Sebastian Schaub, DVM, Dr. med. vet. DipECVDI  
sebast.schaub@gmail.com

**REFERRING VET**

Dr. Matt Haghightat

**INVOICE**

14628

**DATE**

4/6/22