



PATIENT PRESENTING CLINICAL SIGNS

Sadie Zocco hunched back ,stiff gait hind legs, choppy gait no cp deficits, deep pain present . P was given torb

RADIOGRAPHIC STUDY OF THE CERVICAL, THORACIC AND LUMBAR SPINE

SPECIES Radiographs of the entire spine in a two imaging planes are provided for review.

Canine **RADIOGRAPHIC FINDINGS**

BREED The cervical spine is not in the central beam, causing oblique projection of the respective intervertebral disc spaces. The osseous and surrounding soft tissue structures of the cervical spine present without abnormalities.

Havanese The thoracic spine presents without abnormalities.

SEX The intervertebral disc space T13/L1 is narrowed. Mineralized material is superimposed on the intervertebral disc space L5/L6, L6/L7 and L7/S1. The remainder of the osseous and soft tissue structures of the lumbar spine are unremarkable.

Female Mineralized material is seen in the imaging plane of the right renal pelvis.

RADIOGRAPHIC DIAGNOSIS

AGE

13 Years

- Possible discopathy T13/L1
- Chondroid disc degeneration L5/L7, L6/L7 and L7/S1
- Right sided nephrolithiasis
- Normal cervical spine
- Normal thoracic spine

INTERPRETED BY

Sebastian Schaub, DVM
Dr. med. vet. DipECVDI

INTERPRETATION OF THE FINDINGS & FURTHER RECOMMENDATIONS

HOSPITAL NAME

Tenafly Vet Center

The narrowed intervertebral disc space T13/L1 indicates discopathy that might or might not be associated with compressive myelopathy as cause for the described clinical signs.

REFERRING VET

Ohad Barnea

INVOICE

57646

DATE

4-5-23



PATIENT

Sadie Zocco

SPECIES

Canine

BREED

Havanese

SEX

Female

AGE

13 Years

INTERPRETED BY

Sebastian Schaub, DVM
Dr. med. vet. DipECVDI

HOSPITAL NAME

Tenafly Vet Center

REFERRING VET

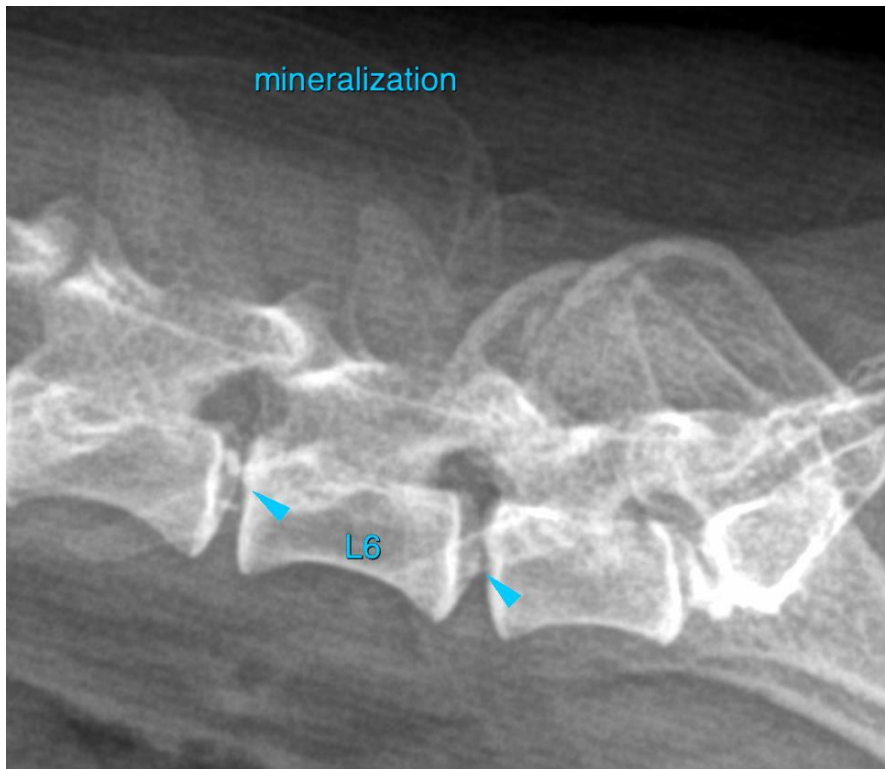
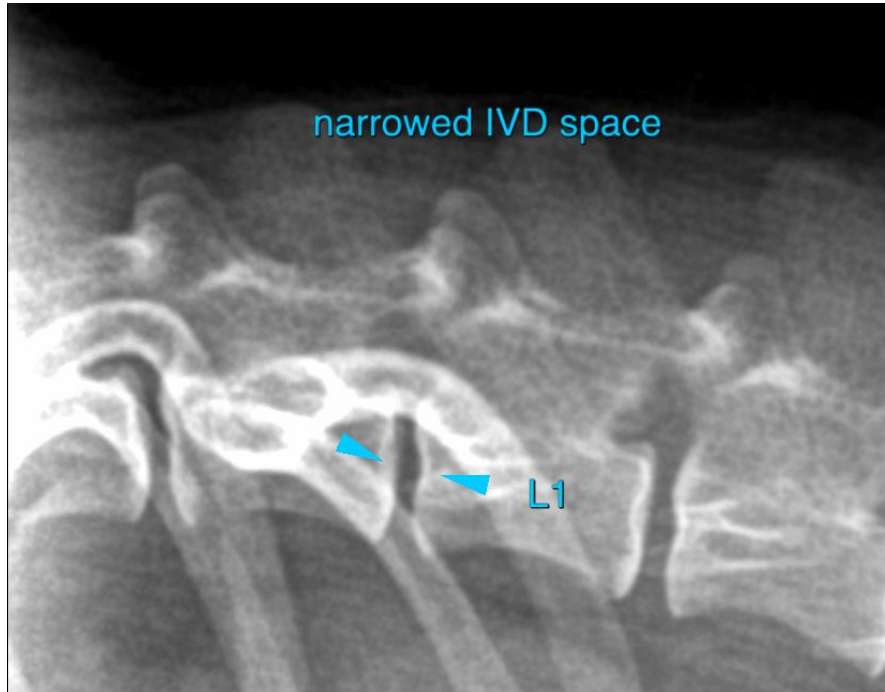
Ohad Barnea

INVOICE

57646

DATE

4-5-23





PATIENT

Sadie Zocco

SPECIES The information and recommendations provided are based on the images presented by the referring veterinarian/sonographer. No evaluation can be communicated regarding pathology that was not visible in the image/video clips provided.

Canine

Thank you for this referral. If the clinical or image interpretation does not parallel your findings or if I can be of any further assistance please contact me.

BREED

Havanese

Sebastian Schaub, Sebastian Schaub, DVM, Dr. med. vet. DipECVDI
sebast.schaub@gmail.com

SEX

Female

AGE

13 Years

INTERPRETED BY

Sebastian Schaub, DVM
Dr. med. vet. DipECVDI

HOSPITAL NAME

Tenafly Vet Center

REFERRING VET

Ohad Barnea

INVOICE

57646

DATE

4-5-23