



PATIENT PRESENTING CLINICAL SIGNS

Bailey Lahti Right forelimb lameness with mass effect over scapular region- open pending further diagnostics.

RADIOGRAPHIC STUDY OF THE THORAX

SPECIES Radiographs of the thorax in three imaging planes are provided for review.

Canine **RADIOGRAPHIC FINDINGS**

The proximal region of the supraspinatus fossa including the spine of the right scapular presents an ill-defined zone with permeative osteolytic lesions and immature mild periosteal new bone formation.

BREED

The extrathoracic soft tissues present homogeneous without abnormalities.

Saint Bernard

The heart is of normal size and shape, there is no evidence of cardiac chamber or vascular enlargement.

SEX

The cranial mediastinum presents the expected soft tissue opacity. The mediastinal width is less than twice the width of the vertebral column at the same level.

Female Spayed

The trachea is normal in diameter and presents the anticipated course. The luminal outline of the trachea is smooth.

AGE

Throughout the lung parenchyma, an innumerable amount of variable sized, well-defined soft tissue opaque nodules is visible.

8 Years, 9 Months

The diaphragm is well delineated with even surface and the expected mild cranial bulging of the diaphragmatic cupola.

INTERPRETED BY

RADIOGRAPHIC DIAGNOSIS

Sebastian Schaub, DVM
Dr. med. vet. DipECVDI

- Monostotic aggressive osteolytic lesion right scapula
- Structured nodular interstitial lung pattern

HOSPITAL NAME

Animal Surgical
Center

INTERPRETATION OF THE FINDINGS & FURTHER RECOMMENDATIONS

The aggressive bone lesion of the right scapula is consistent with primary osseous neoplasia – such as chondrosarcoma, osteosarcoma, fibrosarcoma, round cell tumor, other. FNA sampling of the mass might be considered as advanced diagnostic tool.

REFERRING VET

Three Village
Veterinary Hospital

The pulmonary changes are consistent with pulmonary metastatic spread.

INVOICE

57643

DATE

4-5-23



PATIENT

Bailey Lahti

SPECIES

Canine

BREED

Saint Bernard

SEX

Female Spayed

AGE

8 Years, 9 Months

INTERPRETED BY

Sebastian Schaub, DVM
Dr. med. vet. DipECVDI

HOSPITAL NAME

Animal Surgical
Center

REFERRING VET

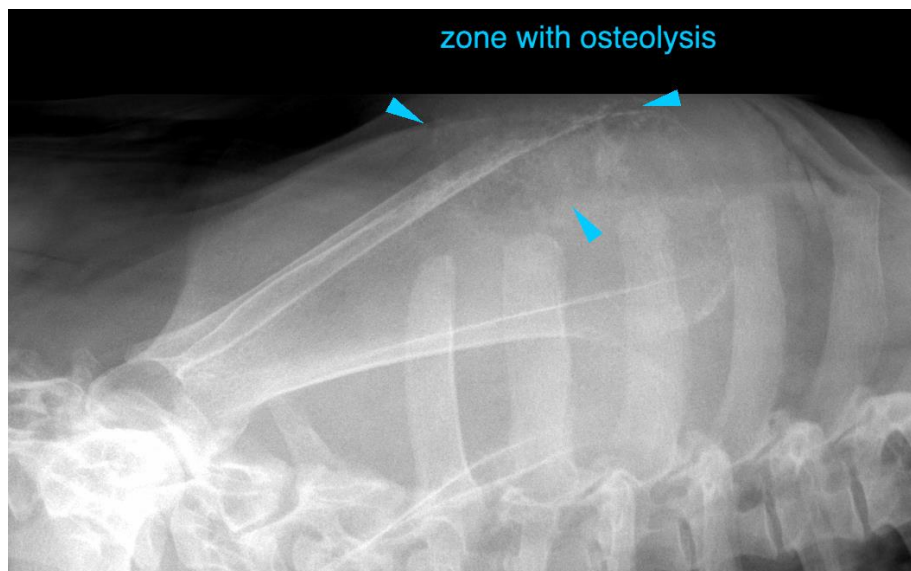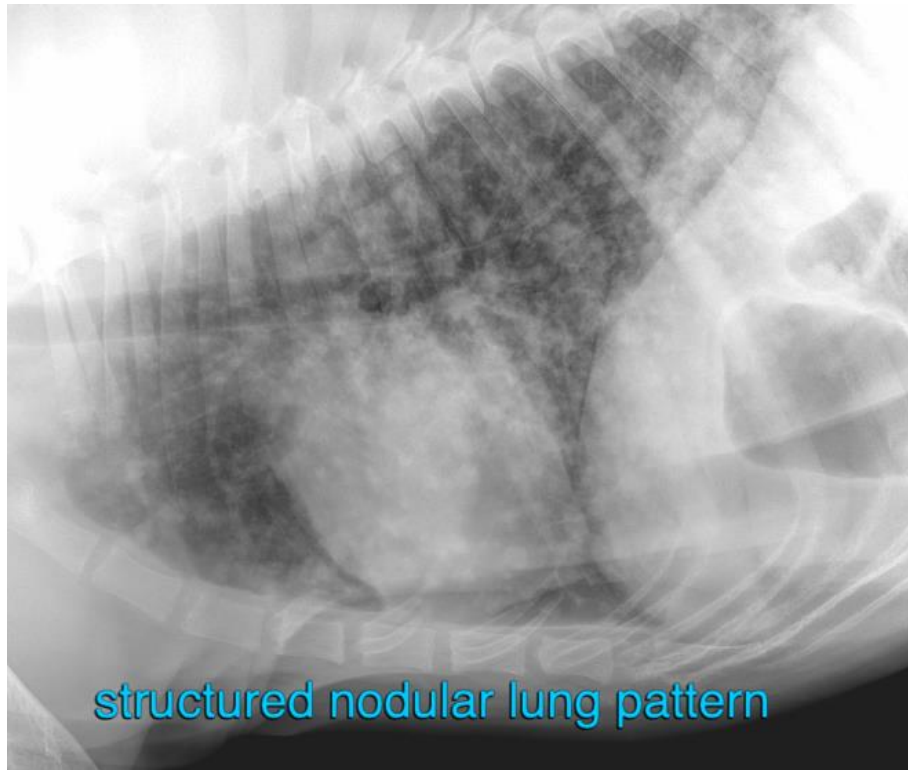
Three Village
Veterinary Hospital

INVOICE

57643

DATE

4-5-23





PATIENT The information and recommendations provided are based on the images presented by the referring veterinarian/sonographer. No evaluation can be communicated regarding pathology that was not visible in the image/video clips provided.
Bailey Lahti

SPECIES Thank you for this referral. If the clinical or image interpretation does not parallel your findings or if I can be of any further assistance please contact me.

Canine **Sebastian Schaub**, Sebastian Schaub, DVM, Dr. med. vet. DipECVDI
sebast.schaub@gmail.com

BREED

Saint Bernard

SEX

Female Spayed

AGE

8 Years, 9 Months

INTERPRETED BY

Sebastian Schaub, DVM
Dr. med. vet. DipECVDI

HOSPITAL NAME

Animal Surgical
Center

REFERRING VET

Three Village
Veterinary Hospital

INVOICE

57643

DATE

4-5-23