



PATIENT PRESENTING CLINICAL SIGNS

Zeus Coulter Hx of congestive heart failure. Started coughing 1 week ago; 1-2x last week, 5-6x this week. Currently on Pimobendan. Was on enalapril, discontinued due to BUN of 79. BUN has improved, now at 50. Abnormal PE/Chem/CBC/UA Results: BCS- WNL Creatinine- WNL

SPECIES RADIOGRAPHIC STUDY OF THE THORAX

CA Radiographs of the thorax in three imaging planes are provided for review.

RADIOGRAPHIC FINDINGS

BREED The surrounding bony structures are within normal limits.

Chihuahua Mix In the subcutaneous tissue of the caudoventral thoracic wall, a spindle shaped fat opaque swelling is seen.

SEX The caudal contour of the cardiac silhouette is steep and the caudal cardiac waist is lost. A wedge shaped soft tissue opacity is seen in the region of the left atrium. In the VD projection, the region of the left ventricle of the heart is prominent. The pulmonary vasculature is within normal limits.

MN

The cranial mediastinum presents the expected soft tissue opacity. The mediastinal width is less than twice the width of the vertebral column at the same level.

AGE

14

The trachea is normal in diameter and presents the anticipated course. The luminal outline of the trachea is smooth.

INTERPRETED BY The bronchial tree presents with thin walls and tapers uniformly towards the periphery as expected.

Sebastian Schaub, DVM Dr. med. vet. DipECVDI The lung parenchyma presents the expected architecture and opacity; the intrapulmonary vascular branching is seen up to the third order lung vessels.

HOSPITAL NAME The diaphragm is well delineated with even surface and the expected mild cranial bulging of the diaphragmatic cupola.

Torch Lake Veterinary Clinic

RADIOGRAPHIC DIAGNOSIS

- Left sided cardiomegaly without signs of decompensation
- Subcutaneous lipoma caudoventral thoracic wall

REFERRING VET INTERPRETATION OF THE FINDINGS & FURTHER RECOMMENDATIONS

A Waffle The radiographic changes are fitting the history of mitral valve insufficiency and secondary left cardiac volume overload – at this point there are no signs for decompensation. A cardiac echo might be used for further assessment of cardiac chamber size and function.

INVOICE

57628

DATE

4-4-23



PATIENT

Zeus Coulter

SPECIES

CA

BREED

Chihuahua Mix

SEX

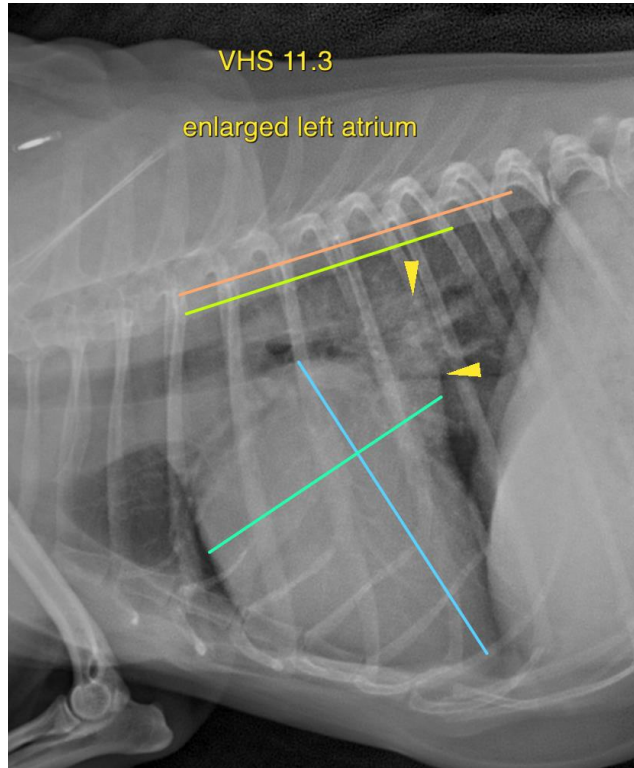
MN

AGE

14

INTERPRETED BY

Sebastian Schaub, DVM
Dr. med. vet. DipECVDI



HOSPITAL NAME

Torch Lake
Veterinary Clinic

The information and recommendations provided are based on the images presented by the referring veterinarian/sonographer. No evaluation can be communicated regarding pathology that was not visible in the image/video clips provided.

Thank you for this referral. If the clinical or image interpretation does not parallel your findings or if I can be of any further assistance please contact me.

REFERRING VET

A Waffle

Sebastian Schaub, Sebastian Schaub, DVM, Dr. med. vet. DipECVDI
sebast.schaub@gmail.com

INVOICE

57628

DATE

4-4-23