



PATIENT PRESENTING CLINICAL SIGNS

Bethoven Perez Patient presented with ataxia and neck pain.

COMPUTED TOMOGRAPHY OF THE SKULL & NECK

SPECIES A pre- and post-contrast CT study of the skull and neck in a bone and soft tissue reconstruction are provided for review.

K9

COMPUTED TOMOGRAPHIC FINDINGS

BREED The pictured parts of the dentition are complete and unremarkable in all jaw quadrants.

Pitbull Both temporomandibular joints present congruent joint spaces with even subchondral bone surfaces and are considered within normal limits.

SEX Both tympanic bullae are aerated, the mucosal lining is not seen, the bony wall is smooth and thin. The horizontal segment of the external ear canals present shell like mineralization.

Male The brain presents no deviation from normal anatomy and symmetry. The brain parenchyma is homogeneous and within normal limits for attenuation and distribution of contrast enhancement. The ventricular system is non-dilated and symmetric.

AGE The submandibular and medial retropharyngeal lymph nodes are small and elongated with a normal short-to-long-axis-ratio is < 0.5, the attenuation and contrast enhancement pattern is uniform.

9

INTERPRETED BY

The intervertebral discs C5/C6 to C7/T1 are mildly bulging into the vertebral canal, occupying approximately up to 15% of the cross-sectional area of the vertebral canal at the same level – most accentuated level C6/C7.

Sebastian Schaub, DVM
Dr. med. vet. DipECVDI

Level with the intervertebral disc space T2/T3, disc material is protruding into the vertebral canal, occupying approximately 30% of the cross-sectional area of the vertebral canal at the same level; the dural tube is mildly deviated dorsally and distorted.

HOSPITAL NAME

COMPUTED TOMOGRAPHIC DIAGNOSIS

JDAH

- Dystrophic mineralization external ear canals
- Intervertebral disc protrusion C5/C6 to C7/T1 and T2/T3 with likely dynamic myelocompression.

REFERRING VET

Jose Rivera

INTERPRETATION OF THE FINDINGS & FURTHER RECOMMENDATIONS

The intervertebral disc protrusion C6/C7 can be a source for intermittent pain but appears unlikely to be associated with neurological deficits. If there was an acute onset of clinical signs, acute on chronic disc disease such as acute non-compressive nucleus pulposus extrusion, ischemic myelopathy might considerations. Depending on development of clinical signs under empirical therapy, workup might be complemented by a myelographic CT study or MRI study of the cervical spine.

INVOICE

58041

DATE

4-30-23



PATIENT

Bethoven Perez

SPECIES

K9

BREED

Pitbull

SEX

Male

AGE

9

INTERPRETED BY

Sebastian Schaub, DVM
Dr. med. vet. DipECVDI

HOSPITAL NAME

JDAH

REFERRING VET

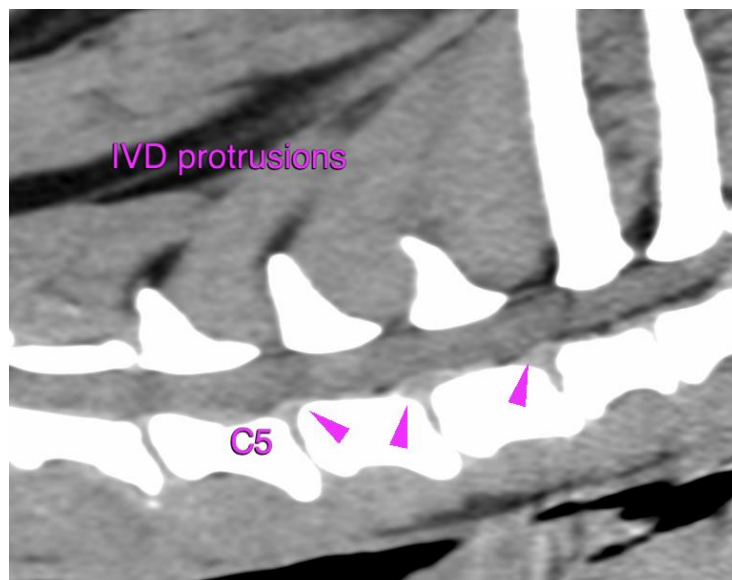
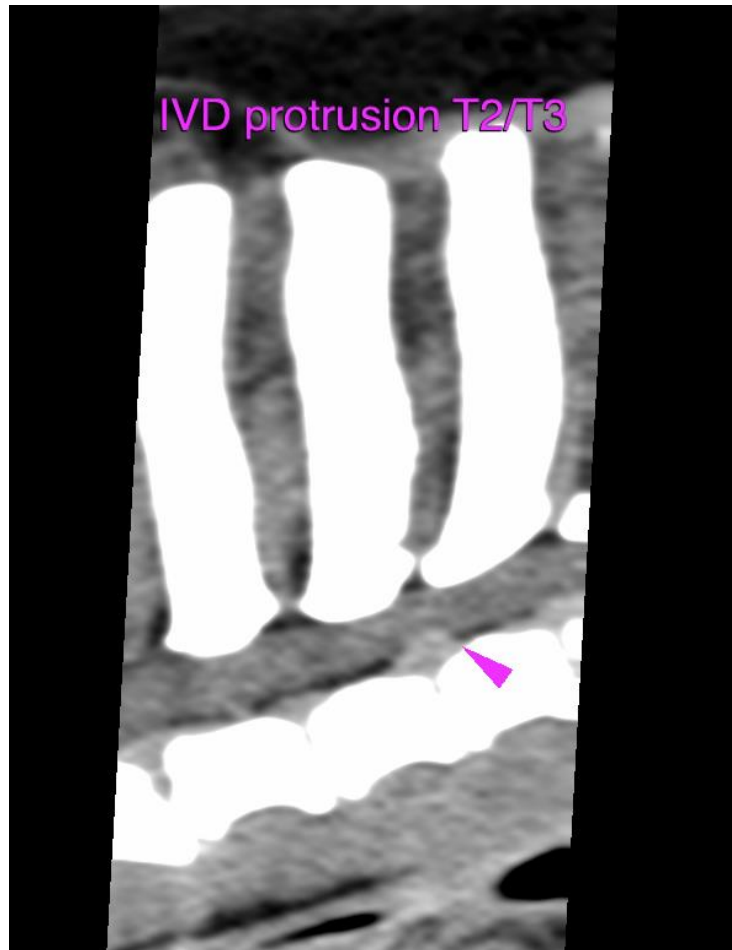Jose Rivera

INVOICE

58041

DATE

4-30-23





PATIENT

Bethoven Perez

SPECIES

K9

The information and recommendations provided are based on the images presented by the referring veterinarian/sonographer. No evaluation can be communicated regarding pathology that was not visible in the image/video clips provided.

Thank you for this referral. If the clinical or image interpretation does not parallel your findings or if I can be of any further assistance please contact me.

BREED

Pitbull

Sebastian Schaub, Sebastian Schaub, DVM, Dr. med. vet. DipECVDI
sebast.schaub@gmail.com

SEX

Male

AGE

9

INTERPRETED BY

Sebastian Schaub, DVM
Dr. med. vet. DipECVDI

HOSPITAL NAME

JDAH

REFERRING VET

Jose Rivera

INVOICE

58041

DATE

4-30-23