



PATIENT

Mauly Olson

SPECIES

Canine

BREED

Coonhound

SEX

Spayed Female

AGE

9 Years

WEIGHT

40.1

INTERPRETED BY

Sebastian Schaub, DVM
Dr. med. vet. DipECVDI

IMAGING PERFORMED BY

Dr. Andrew Burton

HOSPITAL NAME

Mountain West
Veterinary Specialists

REFERRING VET

Dr. Andrew Burton

INVOICE

14869

DATE

04/03/26

PRESENTING CLINICAL SIGNS

- Neurologic: Ataxic in the hind limbs, worse on the left. Significant muscle atrophy of the LH is present. The patient is not placing the left hind paw correctly when placed upside down. Proprioceptive reflexes are decreased in both hind limbs.

MAGNETIC RESONANCE IMAGING OF THE LUMBAR SPINE

T2 and T1 weighted - pre- and post-gadolinium sequences - in multiple imaging planes are provided for review.

MAGNETIC RESONANCE IMAGING FINDINGS

THE LAST LUMBAR VERTEBRA IS COUNTED AS L7.

Level with the intervertebral disc space L6/L7, T2 and T1 hypointense disc material is protruding into the vertebral canal, occupying approximately 25% of the cross-sectional area of the vertebral canal at the same level.

The signal of the in T2w images hyperintense signal of the nucleus pulposus is generalized moderately decreased.

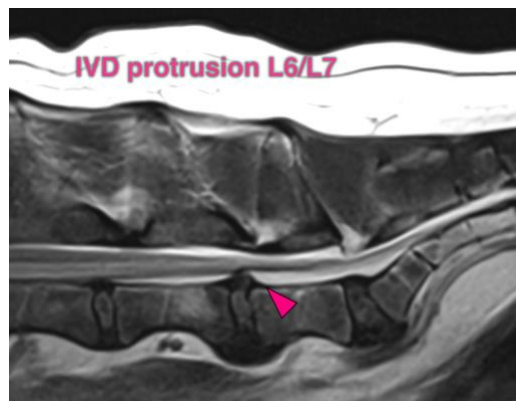
Post contrast administration no pathological contrast uptake is appreciated.

MAGNETIC RESONANCE IMAGING DIAGNOSIS

- Intervertebral disc protrusion on L6/L7 without compressive myelopathy
- Generalized variable degree of degenerative disc disease along the lumbar spine

INTERPRETATION OF THE FINDINGS & FURTHER RECOMMENDATIONS

The MRI study of the lumbar spine reveals no clinically relevant abnormalities and an underlying cause for the presenting neurological signs cannot be specified. Rule out pathology along the cranial segments of the spine versus myelopathy that may present no changes in diagnostic imaging (e.g. degenerative myelopathy).



The information and recommendations provided are based on the images presented by the referring veterinarian/sonographer. No evaluation can be communicated regarding pathology that was not visible in the image/video clips provided.



PATIENT

Mauly Olson

SPECIES

Canine

BREED

Coonhound

SEX

Spayed Female

AGE

9 Years

WEIGHT

40.1

INTERPRETED BY

Sebastian Schaub, DVM
Dr. med. vet. DipECVDI

IMAGING PERFORMED BY

Dr. Andrew Burton

HOSPITAL NAME

Mountain West
Veterinary Specialists

REFERRING VET

Dr. Andrew Burton

INVOICE

14869

DATE

04/03/26

Thank you for this referral. If the clinical or image interpretation does not parallel your findings or if I can be of any further assistance please contact me.

Sebastian Schaub, DVM, Dr. med. vet. DipECVDI
info@sonopath.com