

PATIENT

Enzo Arrazola

SPECIES

Canine

BREED

Golden Retriever

SEX

Male

AGE

1 Year

WEIGHT

65 Pounds

INTERPRETED BY

Sebastian Schaub, DVM
Dr. med. vet. DipECVDI

IMAGING PERFORMED BY

Monika Salgado

HOSPITAL NAME

Westerchester AH

REFERRING VET

Dr. Randy Dominguez

INVOICE

36481

DATE

4/3/26

PRESENTING CLINICAL SIGNS

History: Referred from My Pet Hospital with a BWL of the right P.L. P.E revealed Tibial compression test positive and medial buttress

Abnormal PE/Chem/CBC/UA Results: Unremarkable.

COMPUTED TOMOGRAPHIC STUDY OF THE STIFLE JOINTS

A high resolution pre- and post-contrast CT study of the stifle joints is provided for review.

COMPUTED TOMOGRAPHIC FINDINGS

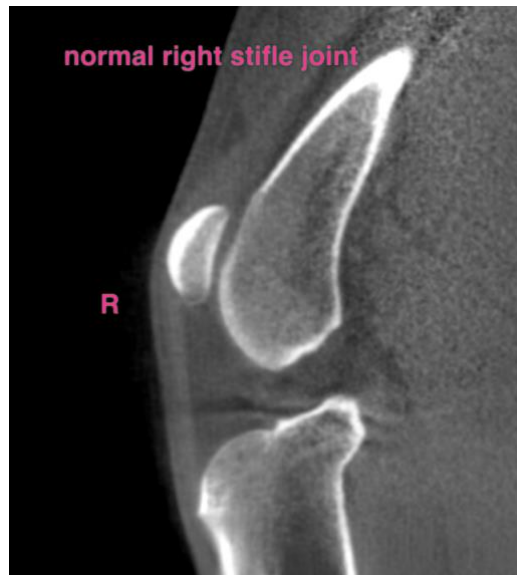Both stifle joints present smooth margins of the periarticular bones – but a bilateral mild irregularity in the region of the closed growth plate. The patella of both stifle joints is in situ. The CT study reveals no evidence of an intracapsular soft tissue swelling. The surrounding soft tissue structures of the stifle joints are within normal limits.

COMPUTED TOMOGRAPHIC DIAGNOSIS

- Normal stifle joints

INTERPRETATION OF THE FINDINGS & FURTHER RECOMMENDATIONS

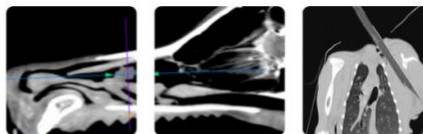
The CT study reveals no abnormalities of the stifle joints.



The information and recommendations provided are based on the images presented by the referring veterinarian/sonographer. No evaluation can be communicated regarding pathology that was not visible in the image/video clips provided.

Thank you for this referral. If the clinical or image interpretation does not parallel your findings or if I can be of any further assistance please contact me.

Sebastian Schaub, DVM, Dr. med. vet. DipECVDI



PATIENT

info@sonopath.com

Enzo Arrazola

SPECIES

Canine

BREED

Golden Retriever

SEX

Male

AGE

1 Year

WEIGHT

65 Pounds

INTERPRETED BY

Sebastian Schaub, DVM
Dr. med. vet. DipECVDI

**IMAGING
PERFORMED BY**

Monika Salgado

HOSPITAL NAME

Westerchester AH

REFERRING VET

Dr. Randy Dominguez

INVOICE

36481

DATE

4/3/26