



**PATIENT PRESENTING CLINICAL SIGNS**

Muffin Ajami Intermittent nwbl in lh for 3-4 months then occurring daily in the past 2 weeks. Very active, hiking and running still. No behavioral changes, no vocalizing. Also sitting weird.

**SPECIES RADIOGRAPHIC STUDY OF THE STIFLE JOINTS**

Canine Radiographs of the stifle joints in two orthogonal imaging planes are provided for review.

**RADIOGRAPHIC FINDINGS**

**BREED** In the craniocaudal view, the stifle joints are in a moderate supinated position.

Mixed The patella of the left stifle joint is superimposed on the medial femoral condyle in the craniocaudal view. The left stifle joint presents a mild intracapsular soft tissue swelling. The osseous margins of both stifle joints are smooth.

**SEX RADIOGRAPHIC DIAGNOSIS**

- Female Spayed
- Suspect left medial patellar luxation
  - Mild articular swelling left stifle joint

**AGE INTERPRETATION OF THE FINDINGS & FURTHER RECOMMENDATIONS**

10 Months The supposed medial patellar luxation can be a plausible underlying entity, explaining the intermittent left hind limb lameness. The mild joint effusion of the left stifle joint is considered as a secondary finding, theoretically pathology of the cranial cruciate ligament or arthritis are considerations, but the odds are low. The radiographic diagnosis has to be confirmed by the clinical examination.

**INTERPRETED BY**

Sebastian Schaub, DVM  
Dr. med. vet. DipECVDI

**HOSPITAL NAME**

Green Dog Dental and  
Wellness

**REFERRING VET**

Dr. Claudia Lau

**INVOICE**

57600

**DATE**

4-3-23



**PATIENT**

Muffin Ajami

**SPECIES**

Canine

**BREED**

Mixed

**SEX**

Female Spayed

**AGE**

10 Months

**INTERPRETED BY**

Sebastian Schaub, DVM  
Dr. med. vet. DipECVDI

**HOSPITAL NAME**

Green Dog Dental and  
Wellness

**REFERRING VET**

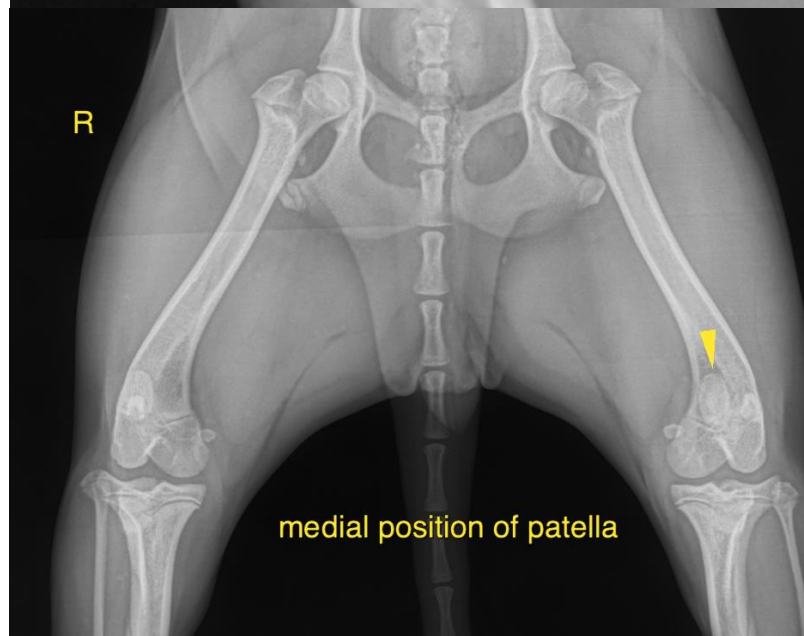
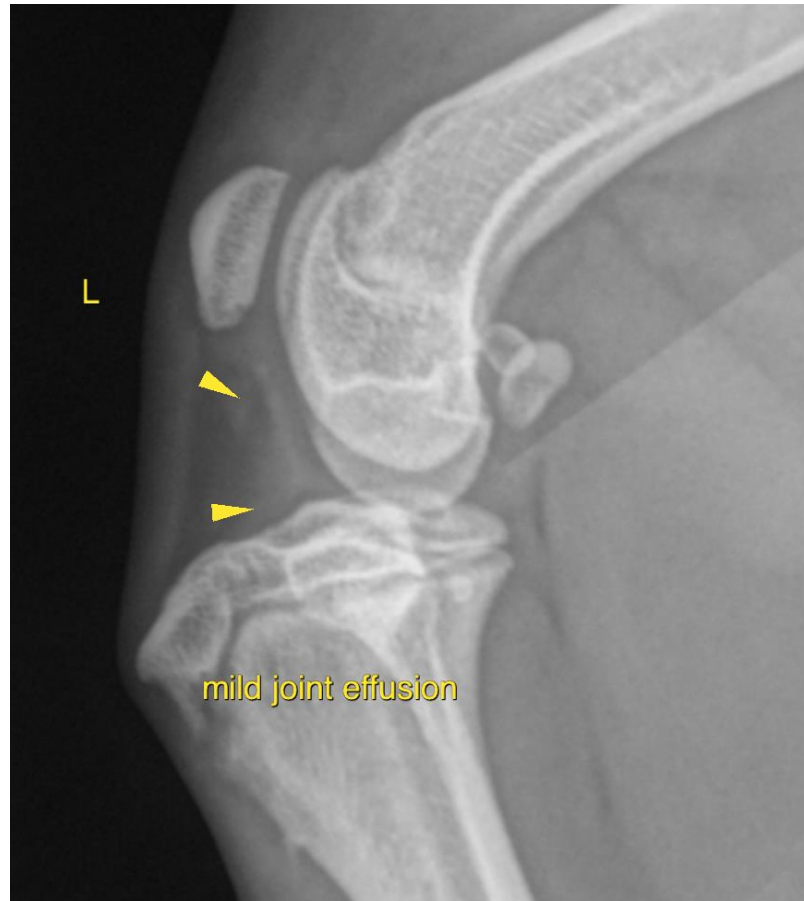
Dr. Claudia Lau

**INVOICE**

57600

**DATE**

4-3-23





**PATIENT**

Muffin Ajami

**SPECIES**

Canine

The information and recommendations provided are based on the images presented by the referring veterinarian/sonographer. No evaluation can be communicated regarding pathology that was not visible in the image/video clips provided.

**BREED**

Mixed

Thank you for this referral. If the clinical or image interpretation does not parallel your findings or if I can be of any further assistance please contact me.

**SEX**

Female Spayed

**Sebastian Schaub**, Sebastian Schaub, DVM, Dr. med. vet. DipECVDI  
sebast.schaub@gmail.com

**AGE**

10 Months

**INTERPRETED BY**

Sebastian Schaub, DVM  
Dr. med. vet. DipECVDI

**HOSPITAL NAME**

Green Dog Dental and  
Wellness

**REFERRING VET**

Dr. Claudia Lau

**INVOICE**

57600

**DATE**

4-3-23