



PATIENT PRESENTING CLINICAL SIGNS

Annie Yoo Lameness of RF leg for the past 3-4 weeks Dog is taking Meloxicam and pregablin for the past 2 years for OA
Abnormal PE/Chem/CBC/UA Results: mild ALT elevation ?

SPECIES RADIOGRAPHIC STUDY OF THE ELBOW JOINTS

Canine Radiographs of the thorax in three imaging planes are provided for review.

RADIOGRAPHIC FINDINGS

BREED
Yorkie X The periarticular bones of both elbow joints present advanced osteophyte new bone formation. Protruding from the caudodistal cutaneous surface of the right brachium, a wart-like lesions is seen.

RADIOGRAPHIC DIAGNOSIS

- SEX**
- Advanced degenerative osteoarthritis elbow joints bilaterally
 - Cutaneous wart-like lesion caudodistal aspect right brachium

FS

INTERPRETATION OF THE FINDINGS & FURTHER RECOMMENDATIONS

AGE
12 Years The radiographic study of the elbow joints presents evidence of advanced degenerative joint disease. The radiographic findings are a plausible cause for the front limb lameness – acute on chronic disease might be a consideration as well.

INTERPRETED BY

Sebastian Schaub, DVM
Dr. med. vet. DipECVDI

HOSPITAL NAME

Balmy Beach Pet Hospital

REFERRING VET

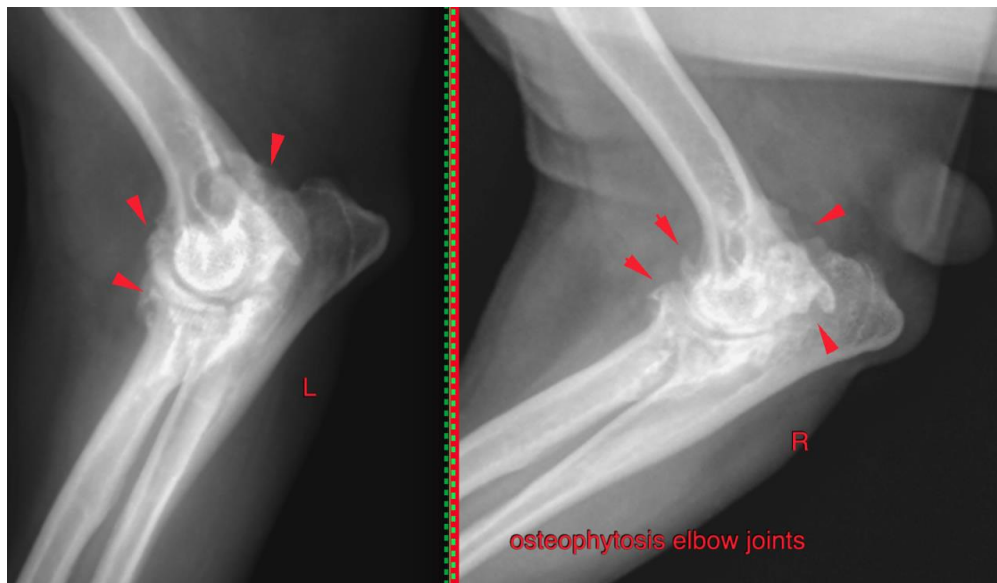
Dr. Singh

INVOICE

57595

DATE

4-3-23





PATIENT

Annie Yoo

The information and recommendations provided are based on the images presented by the referring veterinarian/sonographer. No evaluation can be communicated regarding pathology that was not visible in the image/video clips provided.

SPECIES

Canine

Thank you for this referral. If the clinical or image interpretation does not parallel your findings or if I can be of any further assistance please contact me.

BREED

Yorkie X

Sebastian Schaub, Sebastian Schaub, DVM, Dr. med. vet. DipECVDI
sebast.schaub@gmail.com

SEX

FS

AGE

12 Years

INTERPRETED BY

Sebastian Schaub, DVM
Dr. med. vet. DipECVDI

HOSPITAL NAME

Balmy Beach Pet
Hospital

REFERRING VET

Dr. Singh

INVOICE

57595

DATE

4-3-23