



**PATIENT PRESENTING CLINICAL SIGNS**

Whinny Rhoades 2 days ago stopped eating and drinking. Will only lick some peanut butter. Yesterday she started intermittently yelping and is lip smacking. No activity changes, no vomiting or diarrhea  
 Abnormal PE/Chem/CBC/UA Results: CBC: HCT 43.1%, WBC 6.63, PLT 207 Chem 10: Gluc 105, Creat 1.0, BUN 17, TP 6.1, ALT 39, ALP 24

**SPECIES**

Canine **COMPUTED TOMOGRAPHY OF THE SKULL**

A high resolution post-contrast CT study of the skull is provided for review.

**BREED COMPUTED TOMOGRAPHIC FINDINGS**

Hound Mix The periodontal space of triadan 210 is moderately widened. A tooth element 211 is appreciated, presenting a widened periodontal space.

**SEX** The nasal cavity presents the expected aerated spaces between thin & even conchae and turbinates with smooth mucosal lining.

SF Both temporomandibular joints present congruent joint spaces with even subchondral bone surfaces and are considered within normal limits.

**AGE** Both tympanic bullae are aerated, the mucosal lining is not seen, the bony wall is smooth and thin. The external ear canals are within normal limits.

7 Years The brain presents no deviation from normal anatomy and symmetry. The brain parenchyma is homogeneous and within normal limits for attenuation and distribution of contrast enhancement. The ventricular system is non-dilated and symmetric.

**INTERPRETED BY**

Sebastian Schaub, DVM  
 Dr. med. vet. DipECVDI

The submandibular and medial retropharyngeal lymph nodes are small and elongated with a normal short-to-long-axis-ratio is < 0.5, the attenuation and contrast enhancement pattern is uniform.

The osseous and soft tissue structures of the neck are within normal limits.

**HOSPITAL NAME**

Wilvet Salem

**COMPUTED TOMOGRAPHIC DIAGNOSIS**

- Periodontal disease 210 & 211
- Supernumerary triadan 211

**REFERRING VET**

Dr. Lea Hayes

**INTERPRETATION OF THE FINDINGS & FURTHER RECOMMENDATIONS**

The CT study presents without abnormalities, explaining the described clinical signs. There is no sign for an underlying inflammatory or neoplastic process but the periodontal disease of triadan 210 & 211.

**INVOICE**

58029

**DATE**

4-29-23



**PATIENT**

Whinny Rhoades

**SPECIES**

Canine

**BREED**

Hound Mix

**SEX**

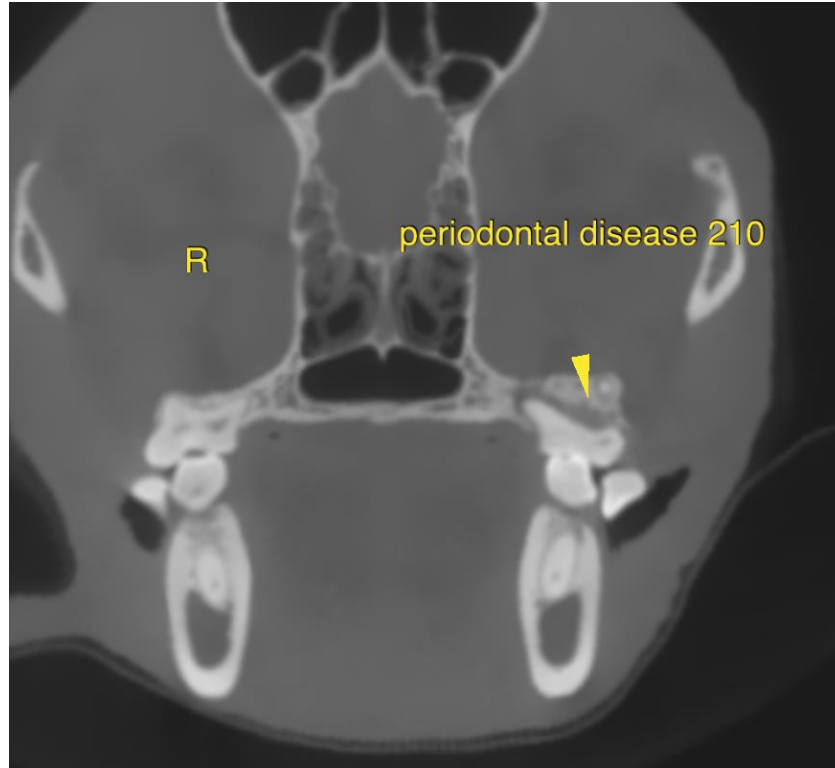
SF

**AGE**

7 Years

**INTERPRETED BY**

Sebastian Schaub, DVM  
Dr. med. vet. DipECVDI



**HOSPITAL NAME**

Wilvet Salem

The information and recommendations provided are based on the images presented by the referring veterinarian/sonographer. No evaluation can be communicated regarding pathology that was not visible in the image/video clips provided.

**REFERRING VET**

Dr. Lea Hayes

Thank you for this referral. If the clinical or image interpretation does not parallel your findings or if I can be of any further assistance please contact me.

**Sebastian Schaub**, Sebastian Schaub, DVM, Dr. med. vet. DipECVDI  
sebast.schaub@gmail.com

**INVOICE**

58029

**DATE**

4-29-23