

**PATIENT PRESENTING CLINICAL SIGNS**

Puppy-"Otto"  
Rushford Regurg. Did barium pass. suspect PRAA

**RADIOGRAPHIC STUDY OF THE THORAX**

**SPECIES** Radiographs of the thorax in three imaging planes are provided for review – including a positive contrast barium swallowing study.

**Ca RADIOGRAPHIC FINDINGS**

The surrounding bony structures are within normal limits.

**BREED** The extrathoracic soft tissues present homogeneous without abnormalities.

Lhasa The heart is of normal size and shape, there is no evidence of cardiac chamber or vascular enlargement. The pulmonary vasculature is within normal limits.

**SEX** The cranial mediastinum presents the expected soft tissue opacity. The mediastinal width is less than twice the width of the vertebral column at the same level.

M The contrast column in the esophagus has the expected course and shape without signs of esophageal dilation or abnormal course. The pictured cervical segment of the esophagus presents focal mild dilation and the contrast media has an irregular shape.

**AGE** The trachea is normal in diameter and presents the anticipated course. The luminal outline of the trachea is smooth.

4 Weeks

**INTERPRETED BY** The bronchial tree presents with thin walls and tapers uniformly towards the periphery as expected.

Sebastian Schaub, DVM  
Dr. med. vet. DipECVDI The lung parenchyma presents the expected architecture and opacity; the intrapulmonary vascular branching is seen up to the third order lung vessels.

The diaphragm is well delineated with even surface and the expected mild cranial bulging of the diaphragmatic cupola.

**HOSPITAL NAME RADIOGRAPHIC DIAGNOSIS**

Bayshore Veterinary  
Hospital

- Possible segmental redundancy of the esophagus cervical segment versus small diverticulum
- Normal thorax

**REFERRING VET INTERPRETATION OF THE FINDINGS & FURTHER RECOMMENDATIONS**

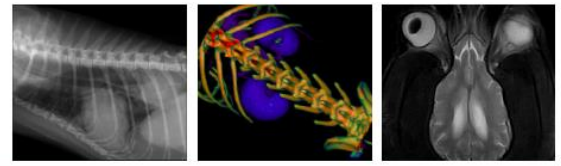
Hunt The focal irregularity of the cervical segment of the esophagus might present a small diverticulum (e.g. secondary to esophageal stricture) or redundancy of the esophagus (might be a source for esophageal dysmotility). The radiographic study is negative for intrathoracic pathology of the esophagus and there are no indirect signs for vascular ring anomaly – such as tracheal deviation, pulsation diverticulum level with the cranial mediastinum. However, in case of doubt, recommend CT study of the thorax to rule out vascular ring anomaly entirely.

**INVOICE**

58035

**DATE**

4-29-23



**PATIENT**

Puppy-"Otto"  
Rushford

**SPECIES**

Ca

**BREED**

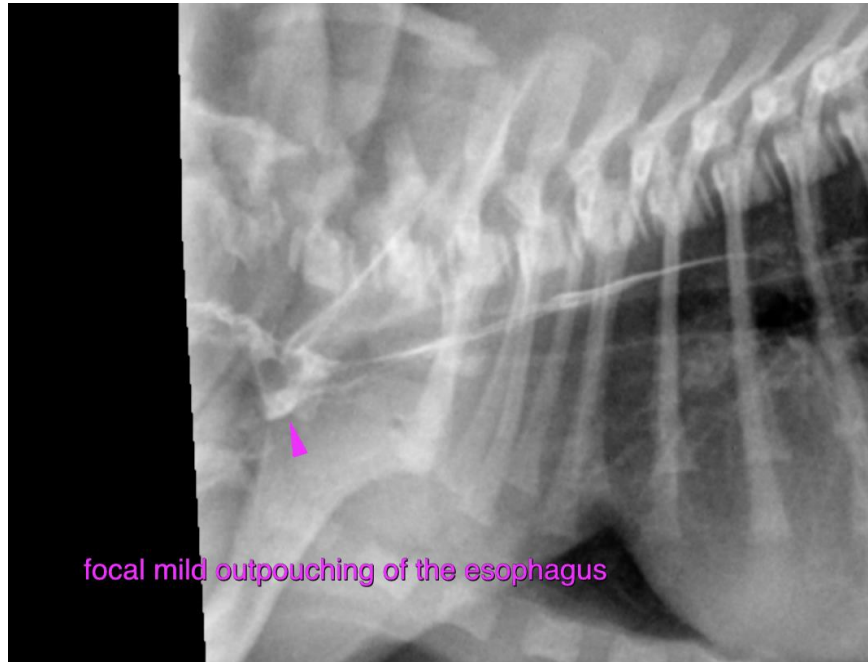
Lhasa

**SEX**

M

**AGE**

4 Weeks



**INTERPRETED BY**

Sebastian Schaub, DVM  
Dr. med. vet. DipECVDI

The information and recommendations provided are based on the images presented by the referring veterinarian/sonographer. No evaluation can be communicated regarding pathology that was not visible in the image/video clips provided.

Thank you for this referral. If the clinical or image interpretation does not parallel your findings or if I can be of any further assistance please contact me.

**HOSPITAL NAME**

Bayshore Veterinary  
Hospital

**Sebastian Schaub**, Sebastian Schaub, DVM, Dr. med. vet. DipECVDI  
sebast.schaub@gmail.com

**REFERRING VET**

Hunt

**INVOICE**

58035

**DATE**

4-29-23