



PATIENT

Lucille Brown

SPECIES

Canine

BREED

English Bulldog

SEX

SF

AGE

1.5 Years

INTERPRETED BY

Sebastian Schaub, DVM
Dr. med. vet. DipECVDI

HOSPITAL NAME

All Creatures Animal
Hospital of South Hill,
Inc.

REFERRING VET

Carolyn Saylor DVM

INVOICE

51829

DATE

4-29-22

PRESENTING CLINICAL SIGNS

Previous slater harris type 1 fracture of the left cranial radius on the left Acute onset of mild intermittent lameness on the left front limb for a couple days R/O DJD in the left elbow secondary to the previous fracture, vs new injury, vs DJD in the left carpus secondary to previous fracture

RADIOGRAPHIC STUDY OF THE LEFT ELBOW JOINT

Radiographs of the left elbow joint in two orthogonal imaging planes are provided for review.

RADIOGRAPHIC FINDINGS

The left radius present a mild to moderate procurvatum conformation. The periarticular bones of the left elbow joint present mild osteophyte new bone formation. In the craniocaudal view of the elbow joint, in the region of the medial coronoid process, two small (< 1.5 mm) are noted. The joint space of the left elbow joint appears congruent.

RADIOGRAPHIC DIAGNOSIS

- Possible fragmented medial coronoid process (FCP) left elbow joint versus metaplasia/synovial osteochondromatosis
- Mild degenerative osteoarthritis left elbow joint
- Procurvatum conformation left radius

INTERPRETATION OF THE FINDINGS & FURTHER RECOMMENDATIONS

The mineralized bodies level with the medial compartment of the left elbow joint are concerning for underlying FPC and secondary mild degenerative joint disease of the left elbow joint. A CT study of the elbow joints can be used as advanced imaging modality for assessing the medial coronoid process.

The procurvatum conformation of the radius might represent a normal anatomical variant and there is no overt incongruity of the elbow joint.



PATIENT

Lucille Brown

SPECIES

Canine

BREED

English Bulldog

SEX

SF

AGE

1.5 Years

INTERPRETED BY

Sebastian Schaub, DVM
Dr. med. vet. DipECVDI

HOSPITAL NAME

All Creatures Animal
Hospital of South Hill,
Inc.

REFERRING VET

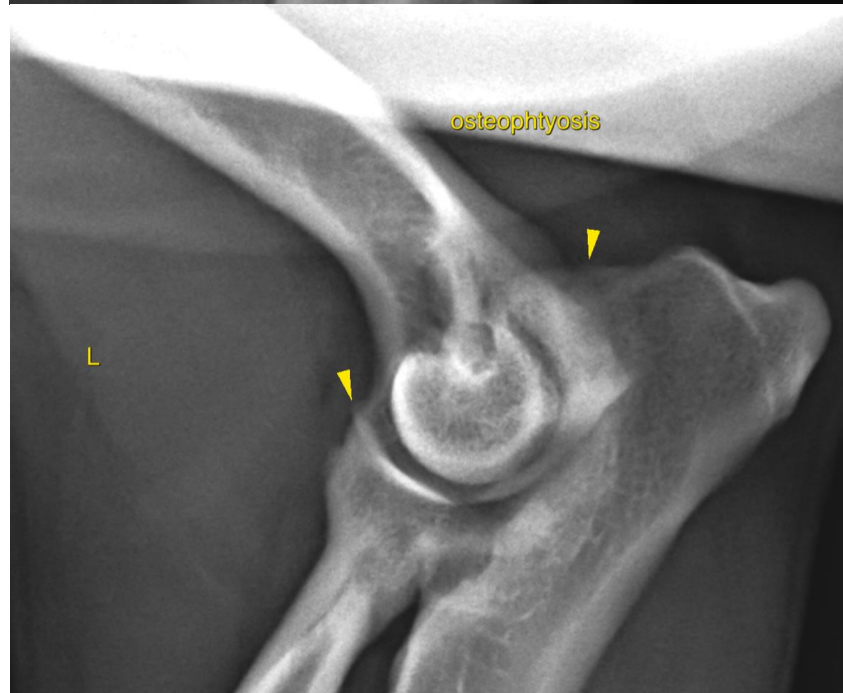
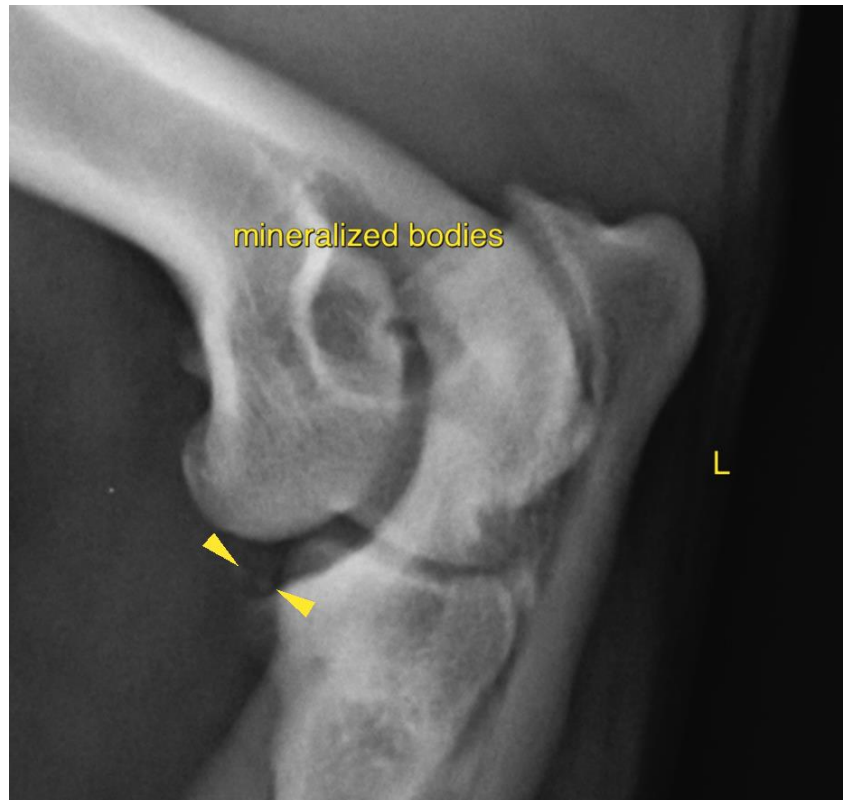
Carolyn Saylor DVM

INVOICE

51829

DATE

4-29-22





PATIENT

Lucille Brown

The information and recommendations provided are based on the images presented by the referring veterinarian/sonographer. No evaluation can be communicated regarding pathology that was not visible in the image/video clips provided.

SPECIES

Canine

Thank you for this referral. If the clinical or image interpretation does not parallel your findings or if I can be of any further assistance please contact me.

Sebastian Schaub, Sebastian Schaub, DVM, Dr. med. vet. DipECVDI
sebast.schaub@gmail.com

BREED

English Bulldog

SEX

SF

AGE

1.5 Years

INTERPRETED BY

Sebastian Schaub, DVM
Dr. med. vet. DipECVDI

HOSPITAL NAME

All Creatures Animal
Hospital of South Hill,
Inc.

REFERRING VET

Carolyn Saylor DVM

INVOICE

51829

DATE

4-29-22