

**PATIENT PRESENTING CLINICAL SIGNS**

Bacardi Bermudez Delayed CP on right hind limb. Recently TPLO left stifle. Previous hemilaminectomy in 2021.

**COMPUTED TOMOGRAPHY OF THE THORACIC & LUMBAR SPINE**

**SPECIES** A high resolution pre- and post-contrast CT study of the thoracic & lumbar spine is provided for review.

Canine **COMPUTED TOMOGRAPHIC FINDINGS**

13 thoracic vertebra and seven lumbar vertebra are present.

**BREED** The vertebral endplates T12/T13 present mild spondylosis formation.

Bichon Frise The left fact joints T13/L1 to L2/L3 are absent and a defect is seen in the left aspect of the lamina, presenting rounded margins.

**SEX** Level with the intervertebral disc spaces L1/L2, L2/L3, L4/L5 and L7/S1 disc material is protruding mild to moderately into the vertebral canal, distorting the epidural space at the same level and is in contact with the dural tube respectively.

Neutered Male

The periarticular bones of the left stifle joint present moderate osteophyte new bone formation, a surgical implant (TPLO plate) is seen at the proximomedial aspect of the left tibia.

**AGE COMPUTED TOMOGRAPHIC DIAGNOSIS**

7 Years, 11 Months

- History of hemilaminectomy T13/L1 to L2/L3
- Intervertebral disc protrusion L1/L2, L2/L3, L4/L5 and L7/S1 with possibly dynamic spinal cord compression
- History of treatment of a cranial cruciate ligament rupture by TPLO left stifle joint
- Moderate degenerative osteoarthritis left stifle joint
- Spondylosis deformans

**INTERPRETED BY**

Sebastian Schaub, DVM  
Dr. med. vet. DipECVDI

**HOSPITAL NAME INTERPRETATION OF THE FINDINGS & FURTHER RECOMMENDATIONS**

Mobile Pet Imaging

The findings of the CT study of the spine present no specific abnormality, explaining the proprioceptive deficits in the hind limbs. The multiple intervertebral disc protrusions can be a source for pain and are considered chronic. If there is suspicion for extrusion of isoattenuating disc material, complementing workup by a myelographic CT study is recommended; an MRI study can be considered alternatively.

**REFERRING VET**

Meaux

**INVOICE**

51826

**DATE**

4-29-22



**PATIENT**

Bacardi Bermudez

**SPECIES**

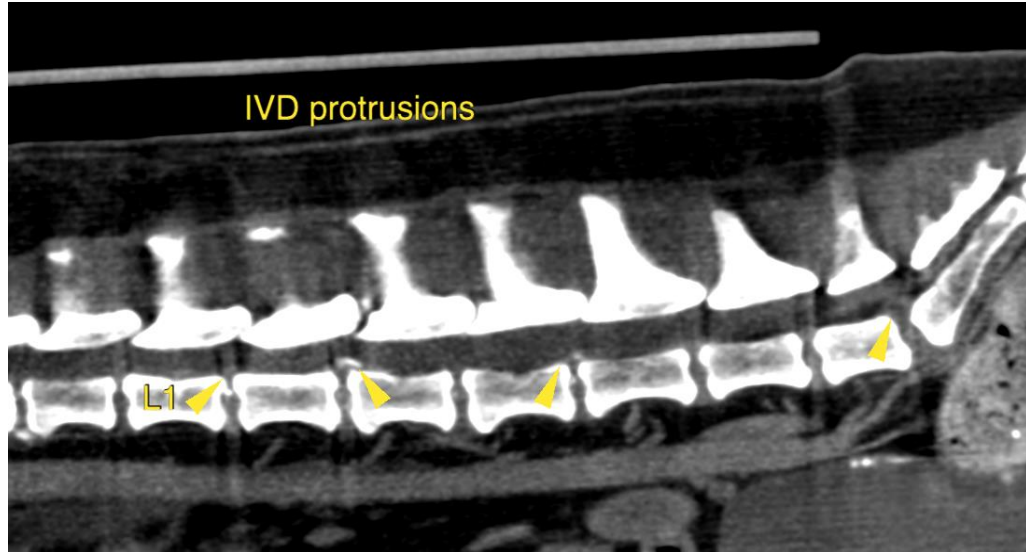
Canine

**BREED**

Bichon Frise

**SEX**

Neutered Male



**AGE**

7 Years, 11 Months

The information and recommendations provided are based on the images presented by the referring veterinarian/sonographer. No evaluation can be communicated regarding pathology that was not visible in the image/video clips provided.

**INTERPRETED BY**

Sebastian Schaub, DVM  
Dr. med. vet. DipECVDI

Thank you for this referral. If the clinical or image interpretation does not parallel your findings or if I can be of any further assistance please contact me.

**Sebastian Schaub**, Sebastian Schaub, DVM, Dr. med. vet. DipECVDI  
sebast.schaub@gmail.com

**HOSPITAL NAME**

Mobile Pet Imaging

**REFERRING VET**

Meaux

**INVOICE**

51826

**DATE**

4-29-22