



PATIENT PRESENTING CLINICAL SIGNS

Larry Caldwell labored breathing and HM grade 4/6 right side
Abnormal PE/Chem/CBC/UA Results: elevated BUN and CREA

SPECIES RADIOGRAPHIC STUDY OF THE THORAX

Canine Radiographs of the thorax in three imaging planes are provided for review.

RADIOGRAPHIC FINDINGS

BREED At the caudal aspect of the glenoid cavity of one shoulder joint, an isolated ossification center is seen.

Terrier Yorkshire The extrathoracic soft tissues present homogeneous without abnormalities.

SEX Soft tissue material is appreciated in the pleural cavity bilaterally, with resulting pleural fissure lines and mild retraction of the lung lobes from the thoracic wall. The cardiac silhouette is partially effaced in the lateral projections. The heart is of normal size and shape, in the VD view. The pulmonary vasculature is within normal limits.

Male Neuter The trachea is normal in diameter and presents the anticipated course. The luminal outline of the trachea is smooth.

AGE The bronchial tree presents with thin walls and tapers uniformly towards the periphery as expected.

11 Years The lung parenchyma presents the expected architecture and opacity; the intrapulmonary vascular branching is seen up to the third order lung vessels.

INTERPRETED BY

The diaphragm is well delineated with even surface and the expected mild cranial bulging of the diaphragmatic cupola.

Sebastian Schaub, DVM
Dr. med. vet. DipECVDI

RADIOGRAPHIC DIAGNOSIS

HOSPITAL NAME

- Moderate pleural effusion
- Isolated ossification center caudal aspect glenoid fossa one scapula

St. Catherine's Animal
Hospital

INTERPRETATION OF THE FINDINGS & FURTHER RECOMMENDATIONS

REFERRING VET

The clinically described labored breathing is a sequela to the pleural effusion – transudate versus exudate. An underlying cause for the pleural effusion is not appreciated in the current radiographic study. Further workup warrants tapping of the pleural effusion including complete fluid analysis.

Dr. Boctor

INVOICE

58034

DATE

4-28-23



PATIENT

Larry Caldwell

SPECIES

Canine

BREED

Terrier Yorkshire

SEX

Male Neuter

AGE

11 Years

INTERPRETED BY

Sebastian Schaub, DVM
Dr. med. vet. DipECVDI

HOSPITAL NAME

St. Catherine's Animal
Hospital

REFERRING VET

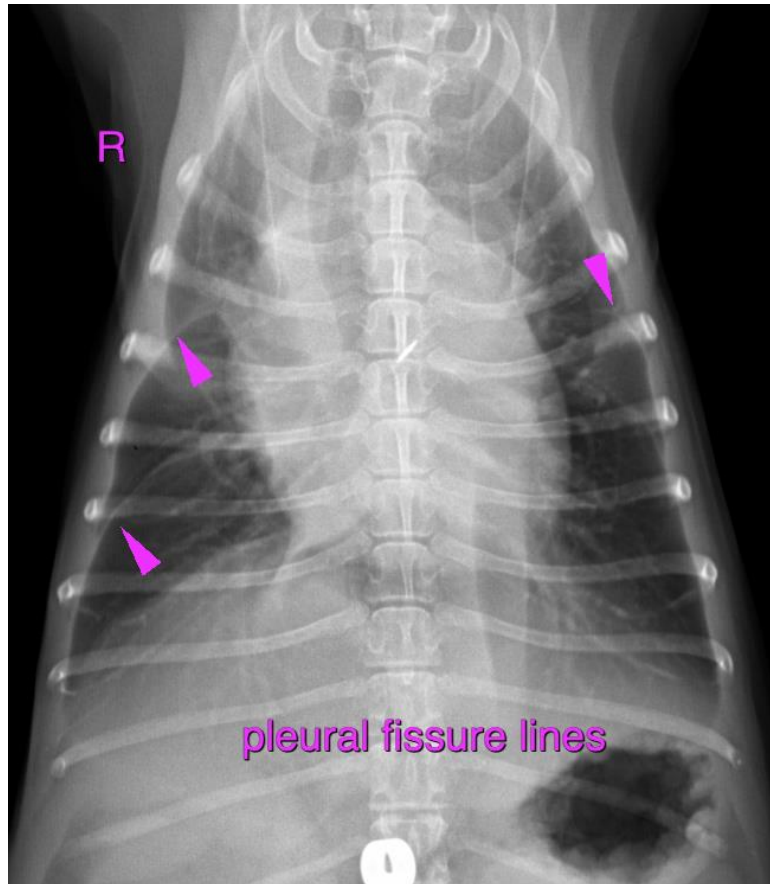
Dr. Boctor

INVOICE

58034

DATE

4-28-23



The information and recommendations provided are based on the images presented by the referring veterinarian/sonographer. No evaluation can be communicated regarding pathology that was not visible in the image/video clips provided.

Thank you for this referral. If the clinical or image interpretation does not parallel your findings or if I can be of any further assistance please contact me.

Sebastian Schaub, Sebastian Schaub, DVM, Dr. med. vet. DipECVDI
sebast.schaub@gmail.com