



PATIENT PRESENTING CLINICAL SIGNS

Oy Sobie History: Mid November 2021 diagnosed with ruptured ear drum, otitis media. Pupils occasionally different sizes. Seemed to respond with 1 month treatment oral Baytril, tympanum regrew. Signs returned in January, treated with Convenia, then another month of Baytril. Pupils still occasionally different sizes. Would like to investigate left middle ear. Hx of chronic back pain, on buprenorphine, meloxicam, gabapentin, methocarbamol, prazosin regularly.

Feline Abnormal PE/Chem/CBC/UA Results: Increased ALT 176 U/L

COMPUTED TOMOGRAPHIC STUDY OF THE SKULL

BREED

DSH A high resolution pre- and post-contrast CT study of the skull is provided for review.

COMPUTED TOMOGRAPHIC FINDINGS

SEX

The tooth elements 106, 107, 206, 307 and 407 are absent.

Neutered Male

The nasal cavity presents the expected aerated spaces between thin & even conchae and turbinates with smooth mucosal lining.

AGE

12 Years

Both temporomandibular joints present congruent joint spaces with even subchondral bone surfaces and are considered within normal limits.

Both tympanic bullae are aerated, the mucosal lining is not seen, the bony wall is smooth and thin. The external ear canals are within normal limits.

INTERPRETED BY

Sebastian Schaub,
DVM Dr. med. vet.
DipECVDI

The brain presents no deviation from normal anatomy and symmetry. The brain parenchyma is homogeneous and within normal limits for attenuation and distribution of contrast enhancement. The ventricular system is non-dilated and symmetric.

HOSPITAL NAME

Bridgwater VH & WC

The submandibular and medial retropharyngeal lymph nodes are small and elongated with a normal short-to-long-axis-ratio is < 0.5, the attenuation and contrast enhancement pattern is uniform.

COMPUTED TOMOGRAPHIC DIAGNOSIS

REFERRING VET

Dr. H. McDonell

- Multiple absent teeth
- No evidence of otitis media or interna

INTERPRETATION OF THE FINDINGS & FURTHER RECOMMENDATIONS

INVOICE

14921

The current CT study of the skull presents without clinically relevant abnormalities. There are no signs for otitis media or interna.

DATE

4/28/22



PATIENT

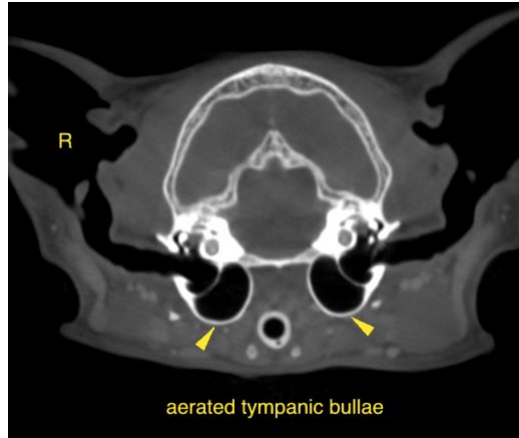
Oy Sobie

SPECIES

Feline

BREED

DSH



SEX

Neutered Male

AGE

12 Years

The information and recommendations provided are based on the images presented by the referring veterinarian/sonographer. No evaluation can be communicated regarding pathology that was not visible in the image/video clips provided.

Thank you for this referral. If the clinical or image interpretation does not parallel your findings or if I can be of any further assistance please contact me.

Sebastian Schaub, Sebastian Schaub, DVM, Dr. med. vet. DipECVDI
sebast.schaub@gmail.com

INTERPRETED BY

Sebastian Schaub,
DVM Dr. med. vet.
DipECVDI

HOSPITAL NAME

Bridgwater VH & WC

REFERRING VET

Dr. H. McDonell

INVOICE

14921

DATE

4/28/22