



PATIENT PRESENTING CLINICAL SIGNS

Cashew Barrett History: Limping on both hind legs
Abnormal PE/Chem/CBC/UA Results: Low total T4

SPECIES RADIOGRAPHIC STUDY OF THE STIFLE JOINTS

Canine Radiographs of the stifle joints in two orthogonal imaging planes are provided for review.

RADIOGRAPHIC FINDINGS

BREED

The body condition score is 9/9.

German Shepherd
Mix

Both coxofemoral joints present advanced osteophyte new bone formation. The acetabular groove bilaterally is shallow, and the center of the femoral heads is lateral to the dorsal acetabular rim. The joint spaces of the coxofemoral joints is incongruent.

SEX

Neutered Male

Both stifle joints present smooth osseous margins without signs of intracapsular swelling.

RADIOGRAPHIC DIAGNOSIS

AGE

2 Years

- Obesity
- Advanced degenerative osteoarthritis coxofemoral joints bilaterally, due to hip dysplasia
- Normal stifle joints

INTERPRETED BY

Sebastian Schaub,
DVM Dr. med. vet.
DipECVDI

INTERPRETATION OF THE FINDINGS & FURTHER RECOMMENDATIONS

The bilateral degenerative joint disease of the coxofemoral joints is considered as the clinically relevant finding in this case. No abnormalities of the stifle joints are appreciated.

HOSPITAL NAME

St. Catharine's AH

Both conservative treatment options – including professional physical therapy, chondroprotective, pain management, intraarticular glucocorticoid injection– or surgical options can be discussed with orthopedic specialist. Weight management is strongly recommended as well.

REFERRING VET

Dr. Boctor

INVOICE

14946

DATE

4/28/22



PATIENT

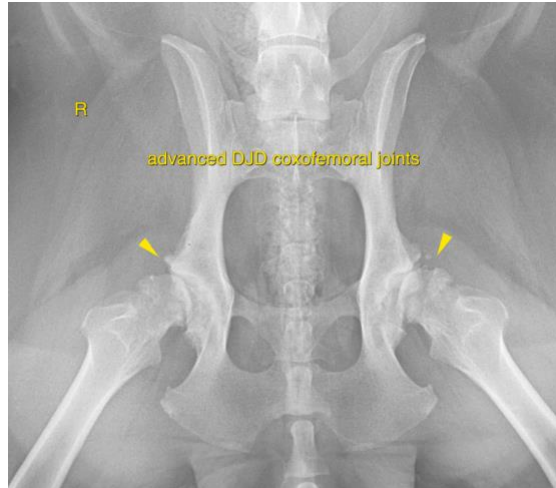
Cashew Barrett

SPECIES

Canine

BREED

German Shepherd
Mix



SEX

Neutered Male

The information and recommendations provided are based on the images presented by the referring veterinarian/sonographer. No evaluation can be communicated regarding pathology that was not visible in the image/video clips provided.

AGE

2 Years

Thank you for this referral. If the clinical or image interpretation does not parallel your findings or if I can be of any further assistance please contact me.

Sebastian Schaub, Sebastian Schaub, DVM, Dr. med. vet. DipECVDI
sebast.schaub@gmail.com

INTERPRETED BY

Sebastian Schaub,
DVM Dr. med. vet.
DipECVDI

HOSPITAL NAME

St. Catharine's AH

REFERRING VET

Dr. Boctor

INVOICE

14946

DATE

4/28/22