



PATIENT

Mickey Farro

SPECIES

Canine

BREED

German Shepherd

SEX

Male Neutered

AGE

5Y

WEIGHT

119lbs

INTERPRETED BY

Sebastian Schaub, DVM
Dr. med. vet.
DipECVDI

IMAGING PERFORMED BY

Dr. Abina Glennon

HOSPITAL NAME

New Bridge Veterinary
Practice

REFERRING VET

Dr. Abina Glennon

INVOICE

74771

DATE

4-27-26

PRESENTING CLINICAL SIGNS

Lame on right and left hind limbs.
Difficulty rising
Stifles feel fine

RADIOGRAPHIC STUDY OF THE PELVIS

A VD view of the pelvis is provided for review.

RADIOGRAPHIC FINDINGS

The periarticular bones of the right coxofemoral joints present moderate osteophyte new bone formation. The joint space of the right coxofemoral joint is incongruent and diverging medially. The center of the right femoral head is lateral to the dorsal acetabular rim.

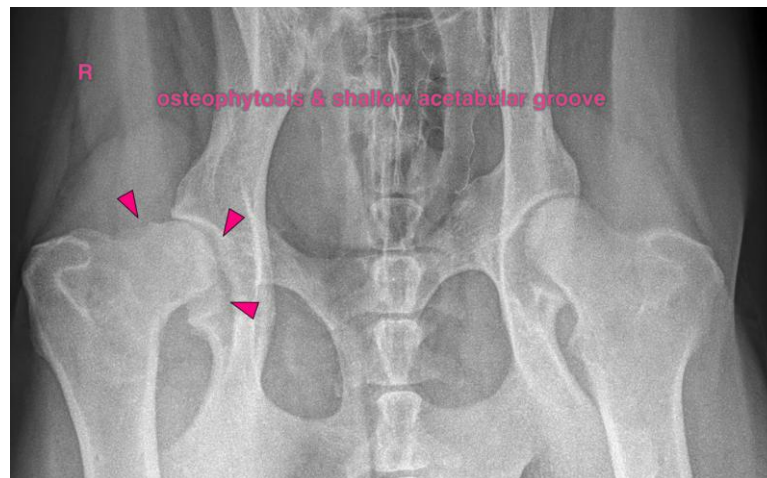
The periarticular bones of the left coxofemoral joint present smooth osseous margins.

RADIOGRAPHIC DIAGNOSIS

- Moderate osteoarthritis right coxofemoral joint due to unilateral hip dysplasia
- Normal left coxofemoral joint

INTERPRETATION OF THE FINDINGS & FURTHER RECOMMENDATIONS

The degenerative joint disease of the right coxofemoral joint can be a cause for the right hind limb lameness. The left coxofemoral joint presents without overt abnormalities.



The information and recommendations provided are based on the images presented by the referring veterinarian/sonographer. No evaluation can be communicated regarding pathology that was not visible in the image/video clips provided.

Thank you for this referral. If the clinical or image interpretation does not parallel your findings or if I can be of any further assistance please contact me.

Sebastian Schaub, Sebastian Schaub, DVM, Dr. med. vet. DipECVDI
info@sonopath.com