



PATIENT

Lady Meow Meow
Fazio

SPECIES

Feline

BREED

Domestic Short Hair

SEX

Female Spayed

AGE

8Y

WEIGHT

11.6

INTERPRETED BY

Sebastian Schaub, DVM
Dr. med. vet.
DipECVDI

IMAGING PERFORMED BY

Dr. Abina Glennon

HOSPITAL NAME

New Bridge Veterinary
Practice

REFERRING VET

Dr. Abina Glennon

INVOICE

74768

DATE

4-27-26

PRESENTING CLINICAL SIGNS

Difficulty breathing, congested and wheezing.

RADIOGRAPHIC STUDY OF THE THORAX

A right lateral view of the thorax is provided for review.

RADIOGRAPHIC FINDINGS

Thorax

The surrounding bony structures are within normal limits.

The extrathoracic soft tissues present homogeneous without abnormalities.

The heart is of normal size and shape; there is no evidence of cardiac chamber or vascular enlargement. The pulmonary vasculature is within normal limits.

The trachea is normal in diameter and presents the anticipated course. The luminal outline of the trachea is smooth.

The bronchial tree presents with thin walls and tapers uniformly towards the periphery as expected.

The lung parenchyma presents the expected architecture and opacity; the intrapulmonary vascular branching is seen up to the third order lung vessels.

The esophagus is mild to moderately distended by gas.

The diaphragm is well delineated with even surface and the expected mild cranial bulging of the diaphragmatic cupola.

RADIOGRAPHIC DIAGNOSIS

- Mild gas distention of the esophagus
- Normal lower airways

INTERPRETATION OF THE FINDINGS & FURTHER RECOMMENDATIONS

The radiographic study reveals no abnormalities of the lower airways that do explain the presenting clinical signs. The gas distended esophagus can be a sequela to aerophagia or can also be appreciated in cases of upper airway obstruction – given the described clinical signs, rule out primary upper airway pathology.

TECHNICAL COMMENTS

Human fingers are seen in the primary beam, please consider radiation safety guidelines!



PATIENT

Lady Meow Meow
Fazio

SPECIES

Feline

BREED

Domestic Short Hair

SEX

Female Spayed

AGE

8Y

WEIGHT

11.6

INTERPRETED BY

Sebastian Schaub, DVM
Dr. med. vet.
DipECVDI

IMAGING PERFORMED BY

Dr. Abina Glennon

HOSPITAL NAME

New Bridge Veterinary
Practice

REFERRING VET

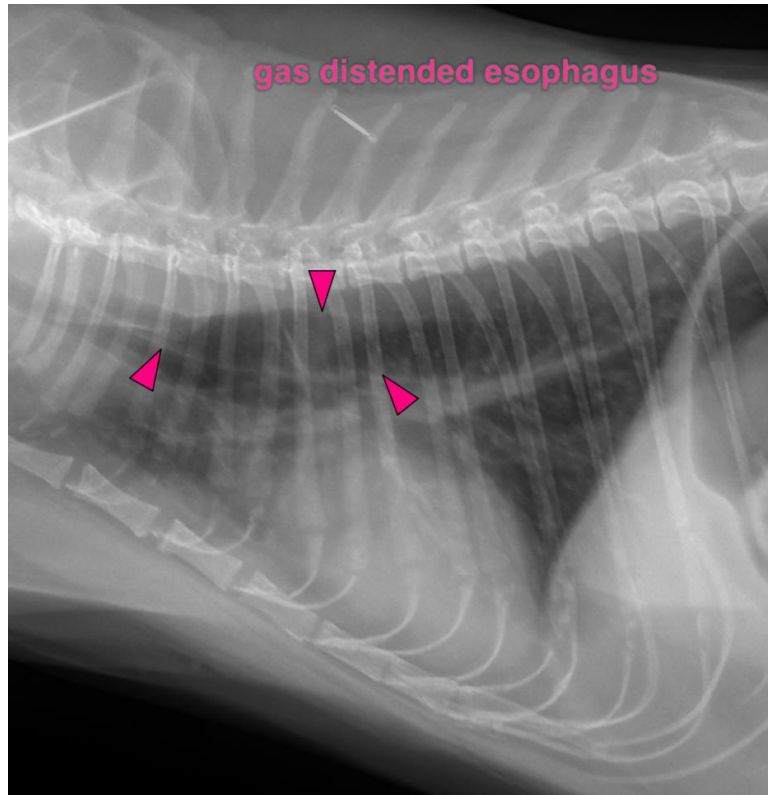
Dr. Abina Glennon

INVOICE

74768

DATE

4-27-26



The information and recommendations provided are based on the images presented by the referring veterinarian/sonographer. No evaluation can be communicated regarding pathology that was not visible in the image/video clips provided.

Thank you for this referral. If the clinical or image interpretation does not parallel your findings or if I can be of any further assistance please contact me.

Sebastian Schaub, Sebastian Schaub, DVM, Dr. med. vet. DipECVDI
info@sonopath.com