



## PATIENT

Charley Christoff

## SPECIES

Canine

## BREED

German Shepherd

## SEX

FS

## AGE

6Y, 1M, 18D

## WEIGHT

20.8kg

## INTERPRETED BY

Sebastian Schaub, DVM  
Dr. med. vet.  
DipECVDI

## IMAGING PERFORMED BY

BO

## HOSPITAL NAME

Green Dog Dental and  
Wellness

## REFERRING VET

Dr. Rally

## INVOICE

74791

## DATE

4-27-26

## PRESENTING CLINICAL SIGNS

Charley presents for possible sprain of right hind leg  
DNA testing revealed half German Shepherd, half Australian cattle dog  
Full checkup performed in August at different veterinary clinic  
Few weeks ago had incident where she vocalized in pain and held right hind leg up  
Walks, eats, sits, and moves around normally  
Runs and spins in yard normally  
Hesitant to jump on bed or sofa (favorite spots)  
Avoids areas near sofa when invited  
Cries and holds leg up when jumping into car  
Client created ramp for sofa access  
Currently resting in crate (happy place)

## RADIOGRAPHIC STUDY OF THE PELVIS AND STIFLE JOINTS

A complete set of radiographs of the pelvis and stifle joints is provided for review.

## RADIOGRAPHIC FINDINGS

The periarticular bones of both coxofemoral joints present mild to moderate osteophyte new bone formation. The joint space of both coxofemoral joints is mildly diverging medially. The center of the femoral heads is level with the dorsal acetabular rim.

Both stifle joints present smooth margins of the periarticular bones and no pathological increased volume of the intracapsular soft tissue shadow. The surrounding soft tissue structures of the stifle joints are within normal limits.

## RADIOGRAPHIC DIAGNOSIS

- Osteoarthritis coxofemoral joints due to hip dysplasia, R>L
- Normal stifle joints

## INTERPRETATION OF THE FINDINGS & FURTHER RECOMMENDATIONS

The degenerative joint disease of the coxofemoral joints is a sequela to hip dysplasia and may trigger the presenting clinical signs. Rule out pathology along the spine as well (e.g. degenerative lumbosacral stenosis).



## PATIENT

Charley Christoff

## SPECIES

Canine

## BREED

German Shepherd

## SEX

FS

## AGE

6Y, 1M, 18D

## WEIGHT

20.8kg

## INTERPRETED BY

Sebastian Schaub, DVM  
Dr. med. vet.  
DipECVDI

## IMAGING PERFORMED BY

BO

## HOSPITAL NAME

Green Dog Dental and  
Wellness

## REFERRING VET

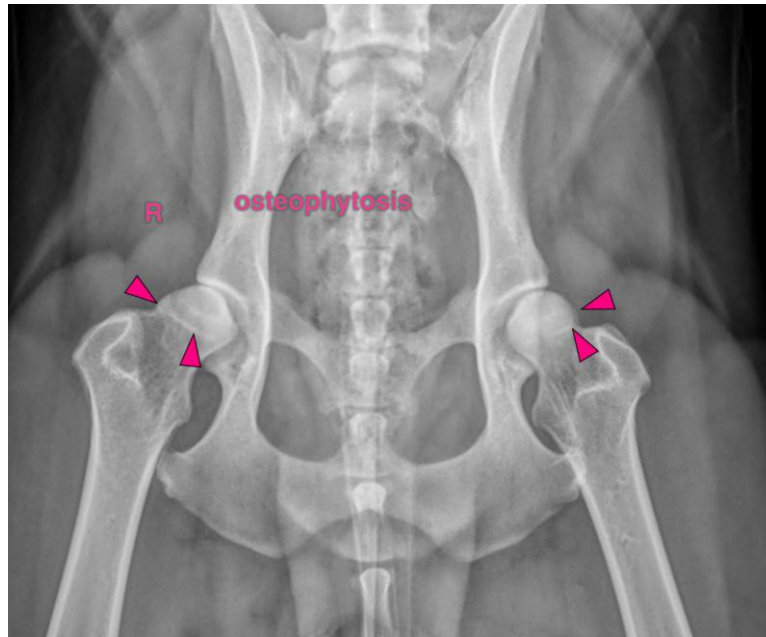
Dr. Rally

## INVOICE

74791

## DATE

4-27-26



The information and recommendations provided are based on the images presented by the referring veterinarian/sonographer. No evaluation can be communicated regarding pathology that was not visible in the image/video clips provided.

Thank you for this referral. If the clinical or image interpretation does not parallel your findings or if I can be of any further assistance please contact me.

**Sebastian Schaub**, Sebastian Schaub, DVM, Dr. med. vet. DipECVDI  
[info@sonopath.com](mailto:info@sonopath.com)