



**PATIENT PRESENTING CLINICAL SIGNS**

Xena Strausser Acute onset hemorrhagic diarrhea, had 1 seizure like episode, has not been regulating glucose, regurgitating, has elevated TBIL and hemoconcentration.

**SPECIES COMPUTED TOMOGRAPHY OF THE ABDOMEN**

Canine A high resolution pre- and post-contrast CT study of the abdomen is provided for review.

**BREED COMPUTED TOMOGRAPHIC FINDINGS**

American Bulldog The serosal fat presents normal attenuation behavior. There is no evidence of peritoneal effusion or peritonitis.

**SEX** Both kidneys present within normal limits for size, shape and organ architecture. After contrast administration a bilaterally symmetric and uniform nephro- and pyelogram is noted.

Spayed Female The adrenal glands are within normal limits for size, shape and organ architecture.

**AGE** Both liver and spleen present with normal shape, even surface, uniformly attenuating parenchyma and homogeneous contrast enhancement, unremarkable.

5 Years Evaluation of the pancreas is limited by mild decreased image contrast and image noise in the cranial abdomen.

**INTERPRETED BY** The stomach is moderately distended by fluid and appears adynamic. The small intestinal loops contain a mild amount of fluid and appear rigid. The colon is mildly distended by fluid attenuating material and the colonic wall is prominent.

Sebastian Schaub, DVM  
Dr. med. vet. DipECVDI

Multifocal moderate spondylosis formation is seen along the lumbar spine.

**HOSPITAL NAME COMPUTED TOMOGRAPHIC DIAGNOSIS**

Aloha Pet & Bird Hospital

- Adynamic appearing gastrointestinal tract
- Moderate fluid distended stomach
- Generalized mild amount of fluid throughout the small and large intestines
- Mild generalized intramural swelling of the colonic wall
- Spondylosis deformans

**REFERRING VET INTERPRETATION OF THE FINDINGS & FURTHER RECOMMENDATIONS**

McLaughlin

**INVOICE** The adynamic appears gastrointestinal tract with the fluid filled stomach in combination with the acute onset of clinical signs is most consistent with hemorrhagic gastroenteritis and secondary functional gastric emptying disorder and colitis. No foreign material is noted throughout the gastrointestinal tract, no mechanical obstruction is appreciated. Complementing blood work by cpl can be used to rule out pancreatitis. Empirical supportive care is indicated.

51777

**DATE** No overt abnormalities of the pancreas are appreciated

4-27-22



**PATIENT**

Xena Strausser

**SPECIES**

Canine

**BREED**

American Bulldog

**SEX**

Spayed Female

**AGE**

5 Years

**INTERPRETED BY**

Sebastian Schaub, DVM  
Dr. med. vet. DipECVDI

**HOSPITAL NAME**

Aloha Pet & Bird  
Hospital

**REFERRING VET**

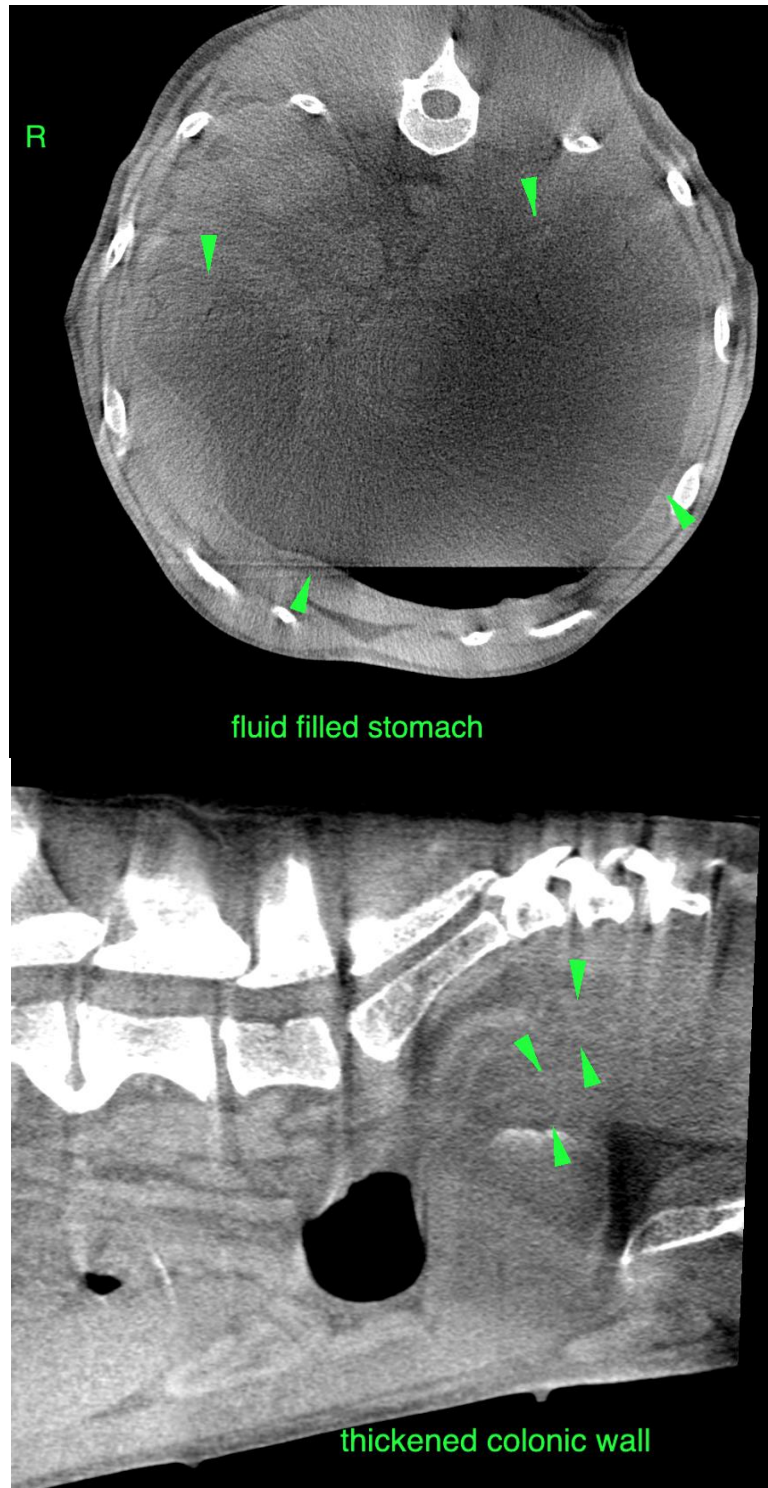
McLaughlin

**INVOICE**

51777

**DATE**

4-27-22





**PATIENT**

Xena Strausser

**SPECIES**

Canine

The information and recommendations provided are based on the images presented by the referring veterinarian/sonographer. No evaluation can be communicated regarding pathology that was not visible in the image/video clips provided.

**BREED**

American Bulldog

Thank you for this referral. If the clinical or image interpretation does not parallel your findings or if I can be of any further assistance please contact me.

**Sebastian Schaub**, Sebastian Schaub, DVM, Dr. med. vet. DipECVDI  
sebast.schaub@gmail.com

**SEX**

Spayed Female

**AGE**

5 Years

**INTERPRETED BY**

Sebastian Schaub, DVM  
Dr. med. vet. DipECVDI

**HOSPITAL NAME**

Aloha Pet & Bird  
Hospital

**REFERRING VET**

McLaughlin

**INVOICE**

51777

**DATE**

4-27-22