



PATIENT

Rocky McCall

SPECIES

Canine

BREED

Labrador Retriever

SEX

Male

AGE

1 Year, 2 Months

INTERPRETED BY

Sebastian Schaub, DVM
Dr. med. vet. DipECVDI

HOSPITAL NAME

Elizabeth Animal
Hospital

REFERRING VET

Leon Anderson, DVM

INVOICE

51804

DATE

4-27-22

PRESENTING CLINICAL SIGNS

Deborah noticed blood 4/18/2022, he was out playing in the pasture and Deborah isn't sure if he got a sticker or cut himself. Rocky was in for a wellness 4/20/2022 and nothing was seen then. Rocky is still limping and it is getting worse. Rocky will still run/walk/play but not for as long and after he runs around he will hold his paw up. He is limping on his R front.

Abnormal PE/Chem/CBC/UA Results: 2/5 RIGHT FRONT LAME. MILD MUSCLE ATROPHY RIGHT FRONT MASS / SKIN TAG (1MMX3MMX4MM) WITH NARROW ATTACHEMENT AND PAINFUL TRACT OF FIRM TISSUE DEEP IN WEB BETWEEN D4&5.

RADIOGRAPHIC STUDY OF THE FRONT LIMBS

A complete set of radiographs of the front limbs is provided for review.

RADIOGRAPHIC FINDINGS

Both shoulder joints present smooth osseous margins and the surrounding soft tissue structures are within normal limits.

The elbow joints present smooth osseous margins and the contour of the medial coronoid process is well-defined. No abnormalities of the soft tissue structures surrounding the elbow joints are appreciated.

The osseous structures of the carpal joints are well-delineated and there are no signs for swelling.

A mild soft tissue swelling is seen between the 4th and 5th digit of the right front paw.

RADIOGRAPHIC DIAGNOSIS

- Mild interdigital swelling 4th&5th digit right front paw
- Normal shoulder joints
- Normal elbow joints
- Normal carpal joints

INTERPRETATION OF THE FINDINGS & FURTHER RECOMMENDATIONS

The soft tissue swelling is fitting the clinically appreciated interdigital swelling due to skin tag/inflammation. The remainder of both front limbs present without abnormalities, explaining the right front limb lameness. No signs for OCD of the shoulder joints or elbow dysplasia.



PATIENT

Rocky McCall

SPECIES

Canine

BREED

Labrador Retriever

SEX

Male

AGE

1 Year, 2 Months

INTERPRETED BY

Sebastian Schaub, DVM
Dr. med. vet. DipECVDI

HOSPITAL NAME

Elizabeth Animal
Hospital

REFERRING VET

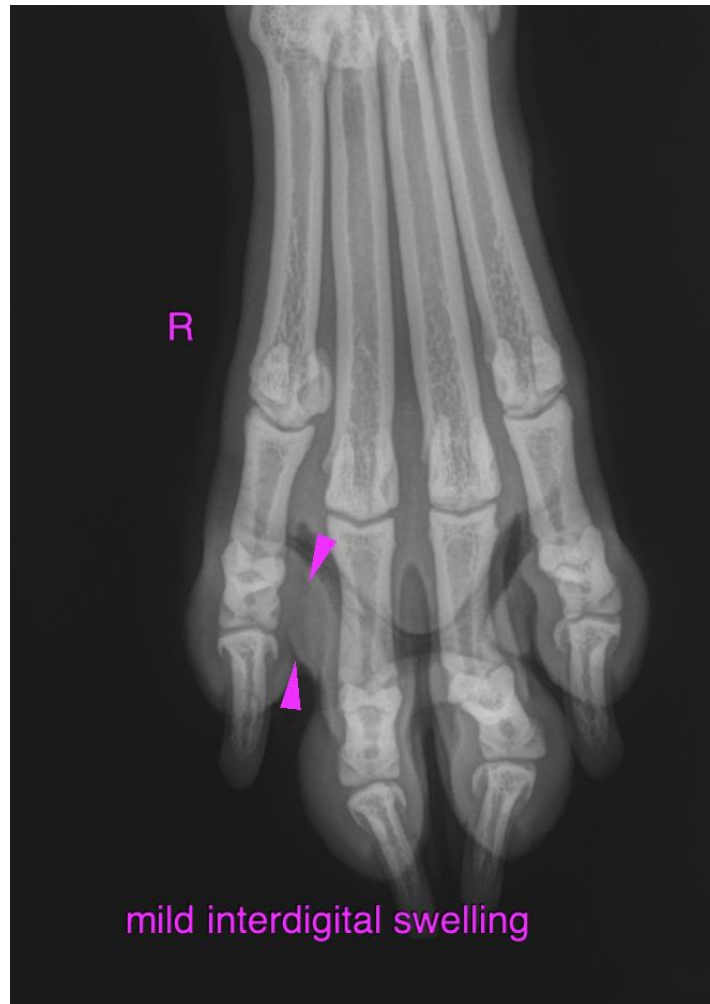
Leon Anderson, DVM

INVOICE

51804

DATE

4-27-22



The information and recommendations provided are based on the images presented by the referring veterinarian/sonographer. No evaluation can be communicated regarding pathology that was not visible in the image/video clips provided.

Thank you for this referral. If the clinical or image interpretation does not parallel your findings or if I can be of any further assistance please contact me.

Sebastian Schaub, Sebastian Schaub, DVM, Dr. med. vet. DipECVDI
sebast.schaub@gmail.com