



**PATIENT**

Prince Villanella

**PRESENTING CLINICAL SIGNS**

P is here to check on vomiting that's been happening for the past two weeks O says P like to pick up acorns off the ground outside, and likes to licks things on the ground on walks, o doesn't know if this happened recently or not and P has a history of having stomach problems ok e/d/u/d no c/s/d on vetoryl for history of Cushing's has insurance eats Lucy's duck and potato LID dry dog food, a little cheese to take the pills o says that lipoma is not getting any bigger

**SPECIES**

Canine

**RADIOGRAPHIC STUDY OF THE THORAX & ABDOMEN**

A complete set of radiographs of the thorax and abdomen is provided for review.

**BREED**

Chihuahua

**RADIOGRAPHIC FINDINGS**

Thorax

The surrounding bony structures are within normal limits.

**SEX**

The extrathoracic soft tissues present homogeneous without abnormalities.

MN

The heart is of normal size and shape, there is no evidence of cardiac chamber or vascular enlargement. The pulmonary vasculature is within normal limits.

**AGE**

6

The cranial mediastinum presents the expected soft tissue opacity. The mediastinal width is less than twice the width of the vertebral column at the same level.

**INTERPRETED BY**

Sebastian Schaub, DVM  
Dr. med. vet. DipECVDI

The trachea is normal in diameter and presents the anticipated course. The luminal outline of the trachea is smooth.

The bronchial tree presents with thin walls and tapers uniformly towards the periphery as expected.

**HOSPITAL NAME**

Animal Paradise  
Hospital

The lung parenchyma presents the expected architecture and opacity; the intrapulmonary vascular branching is seen up to the third order lung vessels.

The diaphragm is well delineated with even surface and the expected mild cranial bulging of the diaphragmatic cupola.

Abdomen

**REFERRING VET**

Dr. Kristen Hellwarth

The caudal aspect of the left iliac wing/left acetabulum present with a chronic healed fracture with medial deviation of the left hemipelvis. The periarticular bones of the left coxofemoral joint present moderate to marked osteophyte new bone formation and the left femoral head is misshapen.

**INVOICE**

51764

No abnormalities of the extraabdominal soft tissues are noted. The abdominal wall is smooth and thin.

The serosal detail is maintained throughout the peritoneal and retroperitoneal space.

The liver is appropriate in position, size and presents uniform opacity.

**DATE**

4-26-22

The splenic head is in the anticipated position and within normal limits for size and opacity. The splenic body and tail are considered normal for position, size, shape and opacity.

Both kidneys are seen and present with normal size, shape, delineation and opacity. The urinary bladder is in its anticipated position. No radiopaque calculi are noted throughout the upper and



**PATIENT**

lower urinary tract.

Prince Villanella

The stomach is in its anticipated position and is empty but a small amount of gas. The gastric wall appears prominent.

**SPECIES**

The small intestinal loops are of even diameter and non-dilated, a small amount of gas is seen within the small intestinal loops and considered within normal limits.

Canine

The colon is seen in the expected position and presents with appropriate content.

**RADIOGRAPHIC DIAGNOSIS**

**BREED**

Chihuahua

- Empty stomach with possible thickening of gastric wall
- Chronic healed left pelvic fracture with evidence of articular fracture of the left coxofemoral joint and advanced degenerative osteoarthritis of the left coxofemoral joint
- Normal thorax

**SEX**

MN

**INTERPRETATION OF THE FINDINGS & FURTHER RECOMMENDATIONS**

The empty stomach ± mural thickening of the gastric wall can indicate gastritis. There is no evidence of radiopaque foreign material or signs for gastrointestinal mechanical obstruction. If not done so yet, recommend complementing workup by complete blood work including cpl to check for underlying pancreatitis.

**AGE**

6

**INTERPRETED BY**

Sebastian Schaub, DVM  
Dr. med. vet. DipECVDI

**HOSPITAL NAME**

Animal Paradise  
Hospital

**REFERRING VET**

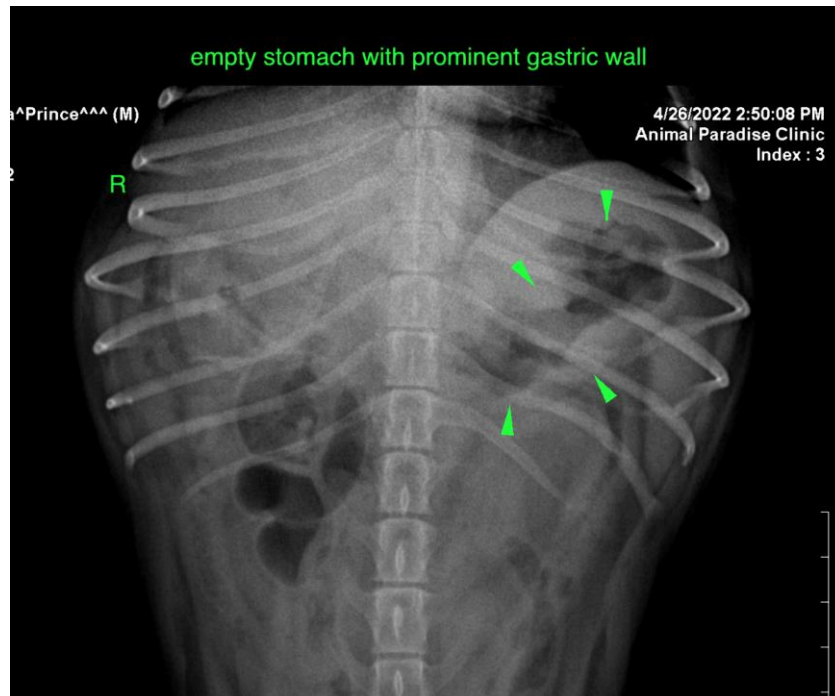
Dr. Kristen Hellwarth

**INVOICE**

51764

**DATE**

4-26-22





**PATIENT**

Prince Villanella

**SPECIES**

Canine

**BREED**

Chihuahua

**SEX**

MN

**AGE**

6

**INTERPRETED BY**

Sebastian Schaub, DVM  
Dr. med. vet. DipECVDI

**HOSPITAL NAME**

Animal Paradise  
Hospital

**REFERRING VET**

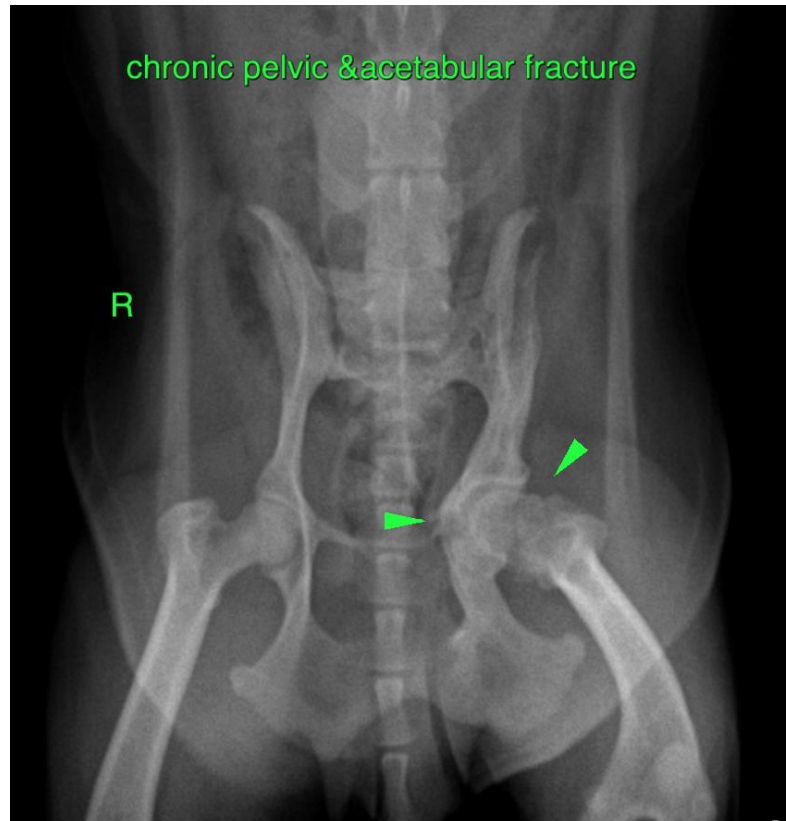
Dr. Kristen Hellwarth

**INVOICE**

51764

**DATE**

4-26-22



The information and recommendations provided are based on the images presented by the referring veterinarian/sonographer. No evaluation can be communicated regarding pathology that was not visible in the image/video clips provided.

Thank you for this referral. If the clinical or image interpretation does not parallel your findings or if I can be of any further assistance please contact me.

**Sebastian Schaub**, Sebastian Schaub, DVM, Dr. med. vet. DipECVDI  
sebast.schaub@gmail.com