



## PATIENT

Maizie McGuire

## SPECIES

Canine

## BREED

Labradoodle

## SEX

Spayed Female

## AGE

6.5 Years

## WEIGHT

43.6 Pounds

## INTERPRETED BY

Sebastian Schaub, DVM  
Dr. med. vet. DipECVDI

## IMAGING PERFORMED BY

Jen Amidon

## HOSPITAL NAME

The Pet Hospital of  
Stratford

## REFERRING VET

Dr. David

## INVOICE

36740

## DATE

4/23/26

## PRESENTING CLINICAL SIGNS

History: Pt has been having diarrhea for 2-3 days, now progressing to vomiting and not wanting to eat today. Pt got at a bunny outside prior to diarrhea starting.

Pt has hx of severe hip dysplasia.

Abnormal PE/Chem/CBC/UA Results: bw/cpl pending

## RADIOGRAPHIC STUDY OF THE ABDOMEN

Radiographs of the abdomen in three imaging planes are provided for review.

## RADIOGRAPHIC FINDINGS

The femoral heads are misshapen and luxated dorsally – forming a

No abnormalities of the extraabdominal soft tissues are noted. The abdominal wall is smooth and thin.

The serosal detail is maintained throughout the peritoneal and retroperitoneal space.

The liver is appropriate in position, size and presents uniform opacity.

The splenic head is in the anticipated position and within normal limits for size and opacity. The splenic body and tail are considered normal for position, size, shape and opacity.

Both kidneys are seen and present with normal size, shape, delineation and opacity. The urinary bladder is in its anticipated position. No radiopaque calculi are noted throughout the upper and lower urinary tract.

The stomach is in its anticipated position and presents normal content.

The small intestinal loops are of even diameter and non-dilated, a small amount of gas is seen within the small intestinal loops and considered within normal limits.

The colon is seen in the expected position and is collapsed, but a small amount of gas.

## RADIOGRAPHIC DIAGNOSIS

- Overall empty gastrointestinal tract
- Severe hip dysplasia with secondary dorsal luxation of the coxofemoral joints

## INTERPRETATION OF THE FINDINGS & FURTHER RECOMMENDATIONS

An underlying cause for the presenting gastrointestinal clinical signs cannot be specified and the presumptive diagnosis is enteritis/gastroenteritis. Rule out gastroenteritis, dysbacteriosis, parasitic infection, dietary indiscretion, pancreatitis, other.



## PATIENT

Maizie McGuire

## SPECIES

Canine

## BREED

Labradoodle

## SEX

Spayed Female

## AGE

6.5 Years

## WEIGHT

43.6 Pounds

## INTERPRETED BY

Sebastian Schaub, DVM  
Dr. med. vet. DipECVDI

## IMAGING PERFORMED BY

Jen Amidon

## HOSPITAL NAME

The Pet Hospital of  
Stratford

## REFERRING VET

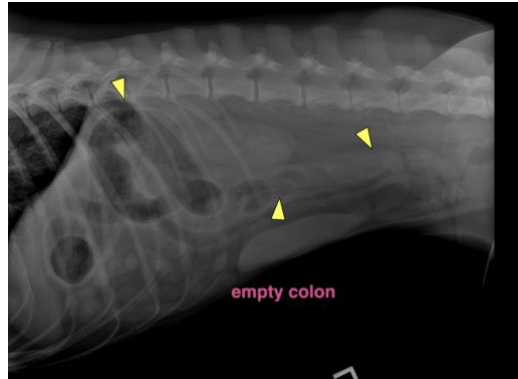
Dr. David

## INVOICE

36740

## DATE

4/23/26



**The information and recommendations provided are based on the images presented by the referring veterinarian/sonographer. No evaluation can be communicated regarding pathology that was not visible in the image/video clips provided.**

Thank you for this referral. If the clinical or image interpretation does not parallel your findings or if I can be of any further assistance please contact me.

**Sebastian Schaub**, DVM, Dr. med. vet. DipECVDI  
[info@sonopath.com](mailto:info@sonopath.com)