



PATIENT

Cu Aomareres

SPECIES

Canine

BREED

Mixed Large Mongrel

SEX

Neutered Male

AGE

9 Months

WEIGHT

30

INTERPRETED BY

Sebastian Schaub, DVM
Dr. med. vet. DipECVDI

IMAGING PERFORMED BY

Eamon

HOSPITAL NAME

Belconnen VC

REFERRING VET

Dr. Eamon

INVOICE

36786

DATE

4/23/26

PRESENTING CLINICAL SIGNS

History: left fore lame isolated to the elbow

Abnormal PE/Chem/CBC/UA Results: cbc/chem not performed

COMPUTED TOMOGRAPHIC STUDY OF THE SHOULDER & ELBOW JOINTS

A pre- and post-contrast CT study of the shoulder and elbow joints in a bone and soft tissue reconstruction is provided for review.

COMPUTED TOMOGRAPHIC FINDINGS

The subchondral bone at the caudal aspect of the humeral head bilaterally presents an irregular concave defect, demarcated by a broad zone of sclerosis, R>L. Post contrast administration the joint capsule of both shoulder joints is mildly thickened and bilaterally a mild intracapsular fluid attenuating filling of the shoulder joints is seen.

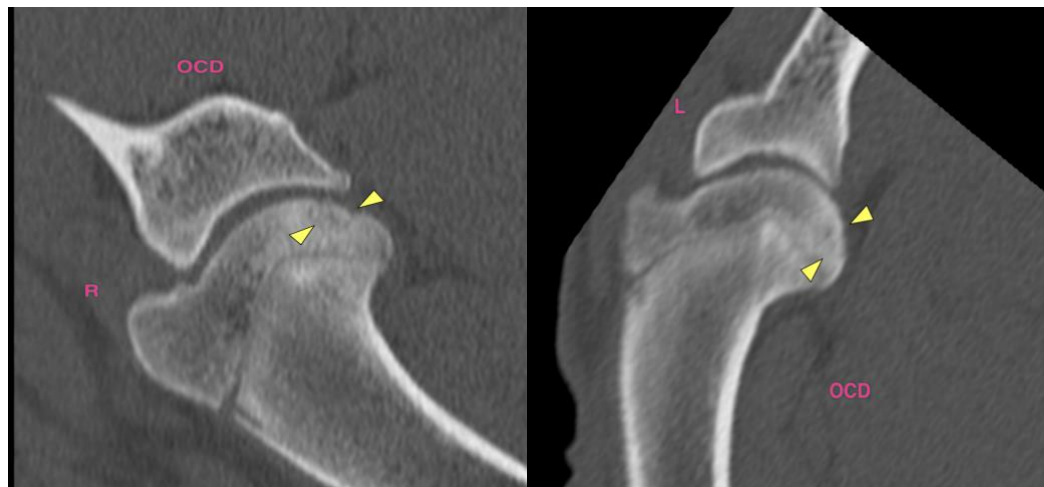
Both elbow joints present smooth margins of the periarticular bones. The medial coronoid process of both elbow joints is well-defined and has a homogeneous density, unremarkable. The joint space of both elbow joints is mildly incongruent. The surrounding soft tissue structures of the elbow joints reveal no abnormalities.

COMPUTED TOMOGRAPHIC DIAGNOSIS

- Osteochondrosis dissecans (OCD) humeral head bilaterally, R>L
- Synovitis and mild effusion shoulder joint bilaterally
- Normal elbow joints, but very mild incongruity of the humero-ulnar joint bilaterally

INTERPRETATION OF THE FINDINGS & FURTHER RECOMMENDATIONS

The main finding is the OCD lesion of both shoulder joints that may be a trigger for front limb lameness. The elbow joints reveal no clinically relevant abnormalities.



The information and recommendations provided are based on the images presented by the referring veterinarian/sonographer. No evaluation can be communicated regarding pathology



PATIENT

Cu Aomareres

SPECIES

Canine

BREED

Mixed Large Mongrel

SEX

Neutered Male

AGE

9 Months

WEIGHT

30

INTERPRETED BY

Sebastian Schaub, DVM
Dr. med. vet. DipECVDI

IMAGING PERFORMED BY

Eamon

HOSPITAL NAME

Belconnen VC

REFERRING VET

Dr. Eamon

INVOICE

36786

DATE

4/23/26

that was not visible in the image/video clips provided.

Thank you for this referral. If the clinical or image interpretation does not parallel your findings or if I can be of any further assistance please contact me.

Sebastian Schaub, DVM, Dr. med. vet. DipECVDI

info@sonopath.com