



PATIENT

Arya Roxbury

PRESENTING CLINICAL SIGNS

4 days ago Arya was playing in the yard and owner noticed she was limping on her right front leg. Not sure what could have caused it but it isn't getting any better. A lot of times she will hold it up. When palpated she jerked back when messing with her toes. She still wanted to play yesterday though.

SPECIES

Canine

Abnormal PE/Chem/CBC/UA Results: Pain on flexion of right carpus and mild effusion

BREED

Border Collie

RADIOGRAPHIC STUDY OF THE CARPAL JOINTS

Radiographs of the carpal joints in two imaging planes are provided for review.

RADIOGRAPHIC FINDINGS

The radiographic study of the right carpal joint presents moderate osteophyte new bone formation and a mild to moderate circumferential soft tissue swelling of the right carpal joint is appreciated, distorting the fascial plane dorsal to the carpal joint.

SEX

FS

The periarticular bones of the left carpal joint present mild osteophyte new bone formation. There is a mild increased intracapsular swelling of the left carpal joint.

AGE

7 Years, 4 Months

Multiple metacarpophalangeal joints of both front paws present moderate osteophyte new bone formation.

The proximal interphalangeal joint of the second and fifth digit present moderate enthesophyte formation.

INTERPRETED BY

Sebastian Schaub, DVM
Dr. med. vet. DipECVDI

RADIOGRAPHIC DIAGNOSIS

- Mild degenerative osteoarthritis carpal joints bilaterally
- Mild to moderate articular swelling carpal joints bilaterally
- Degenerative osteoarthritis metacarpophalangeal joints of both front paws
- Degenerative osteoarthritis proximal interphalangeal joints second & fifth phalanx front paws bilaterally

HOSPITAL NAME

Elizabeth Animal Hospital

INTERPRETATION OF THE FINDINGS & FURTHER RECOMMENDATIONS

Both carpal joints (R>L), metacarpophalangeal joints and interphalangeal joints of both front limbs present signs of degenerative joint disease and acute on chronic insult may have triggered the lameness. The effusion of the right carpal joint can be degenerative or traumatic in origin; to rule out immune mediated arthritis or infectious origin a synovial tap can be used as advanced diagnostic tool. If there are signs for instability of the carpal joint, consider stressed radiographs under general anesthesia.

REFERRING VET

Leon Anderson, DVM

INVOICE

51706

DATE

4-23-22



PATIENT

Arya Roxbury

SPECIES

Canine

BREED

Border Collie

SEX

FS

AGE

7 Years, 4 Months

INTERPRETED BY

Sebastian Schaub, DVM
Dr. med. vet. DipECVDI

HOSPITAL NAME

Elizabeth Animal
Hospital

REFERRING VET

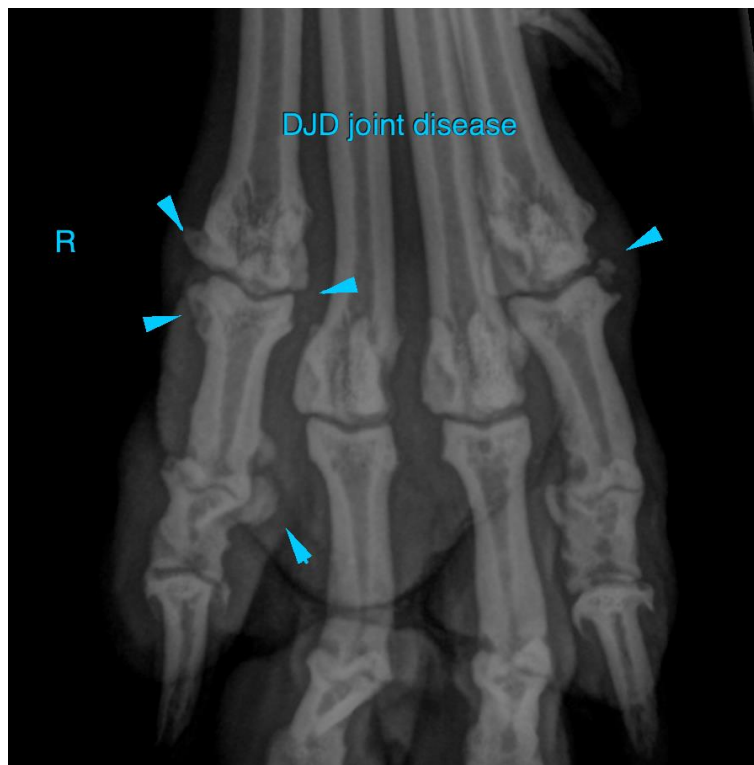
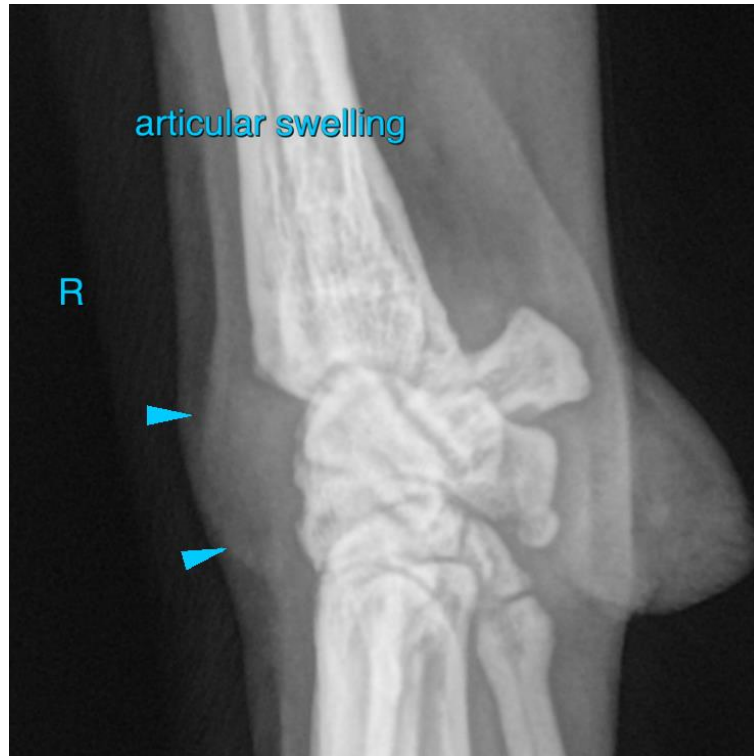
Leon Anderson, DVM

INVOICE

51706

DATE

4-23-22





PATIENT

Arya Roxbury

The information and recommendations provided are based on the images presented by the referring veterinarian/sonographer. No evaluation can be communicated regarding pathology that was not visible in the image/video clips provided.

SPECIES

Canine

Thank you for this referral. If the clinical or image interpretation does not parallel your findings or if I can be of any further assistance please contact me.

BREED

Border Collie

Sebastian Schaub, Sebastian Schaub, DVM, Dr. med. vet. DipECVDI
sebast.schaub@gmail.com

SEX

FS

AGE

7 Years, 4 Months

INTERPRETED BY

Sebastian Schaub, DVM
Dr. med. vet. DipECVDI

HOSPITAL NAME

Elizabeth Animal
Hospital

REFERRING VET

Leon Anderson, DVM

INVOICE

51706

DATE

4-23-22