



PATIENT PRESENTING CLINICAL SIGNS

PATIENT
Chewy Martin

SPECIES
Dog

Transient vestibular episodes (0-2 a month) since January 2022. Started to be lethargic on April 15th and sudden left head tilt on April 21st with spontaneous nystagmus and left facial paralysis
Neurolocalization: left sided central vestibular system + left nerve VII and VIII dysfunction and delayed postural reactions on the right side (multifocal ?) Severe myositis OS: corneal ulcer
Abnormal PE/Chem/CBC/UA Results: April 17th: CBC and biochemistry WNL CSF analysis: 62cells/uL. Microprotein pending.

MAGNETIC RESONANCE IMAGING OF THE SKULL

BREED
Frenchie

T2 weighted, FLAIR, diffusion weighted, SWI, T1 pre- and post-gadolinium sequence in multiple imaging planes are provided for review.

MAGNETIC RESONANCE IMAGING FINDINGS

SEX
Male

The brain presents the expected anatomy. Post contrast administration, the pachymeninx along the left cerebellar hemispheres and left lateroventral aspect of the caudal cranial fossa is moderately thickened and presents significant contrast enhancing as well as the region of the left facial and vestibulocochlear nerve. The left cerebellar hemisphere and brainstem present a mild FLAIR hyperintense signal in the periphery.

AGE
5 Years

The ventricular system presents the expected dimensions, morphology and the CSF signal is within normal limits in all sequences.

Aberrant growth of the nasal conchal structures is appreciated.

INTERPRETED BY

Sebastian Schaub, DVM
Dr. med. vet. DipECVDI

The endolymph of the left inner ear is not suppressed in the FLAIR and mild contrast enhancement is seen within the left inner ear.

The tympanic bullae contain a moderate amount of FLAIR&T2 hyperintense material. The wall of the left external ear canal is moderately thickened and presents moderate contrast enhancing.

HOSPITAL NAME

Animal Health
Partners

A small polypoid T2 hyperintense, moderate contrast enhancing lesion is protruding from the roof of the nasopharynx.

MAGNETIC RESONANCE IMAGING DIAGNOSIS

REFERRING VET

Dr. Greg Kilburn

- Pachymeningitis region of the left temporal bone and left cerebellar hemisphere and accompanying FLAIR hyperintensity of the associated parenchyma of the brain
- Left sided otitis interna
- Left sided otitis externa
- Otitis media bilaterally, likely secretory
- Small polypoid lesion roof of nasopharynx
- Aberrant conchal growth

INVOICE

51698

INTERPRETATION OF THE FINDINGS & FURTHER RECOMMENDATIONS

DATE

4-22-22

The findings are supporting the diagnosis of left sided otitis externa, media and interna with intracranial extend and secondary (septic) meningoencephalitis and neuritis of the left cranial nerves VII and VIII.

Surgical management of the otitis media appears beneficial as well as aggressive antimicrobial



PATIENT

therapy using drugs crossing the blood brain barrier.

Chewy Martin

SPECIES

Dog

BREED

Frenchie

SEX

Male

AGE

5 Years

INTERPRETED BY

Sebastian Schaub, DVM
Dr. med. vet. DipECVDI

HOSPITAL NAME

Animal Health
Partners

REFERRING VET

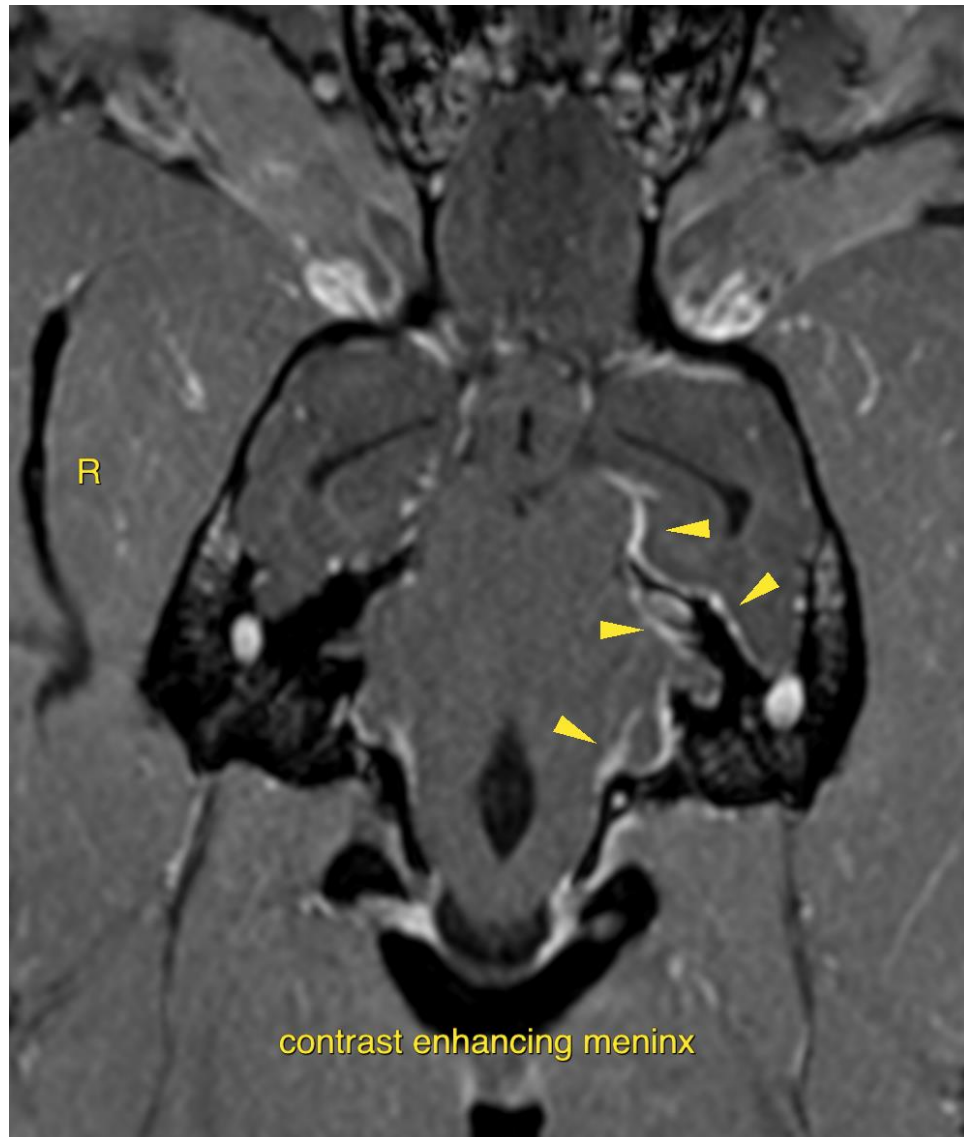
Dr. Greg Kilburn

INVOICE

51698

DATE

4-22-22





PATIENT

Chewy Martin

SPECIES

Dog

BREED

Frenchie

SEX

Male

AGE

5 Years

INTERPRETED BY

Sebastian Schaub, DVM
Dr. med. vet. DipECVDI

HOSPITAL NAME

Animal Health
Partners

REFERRING VET

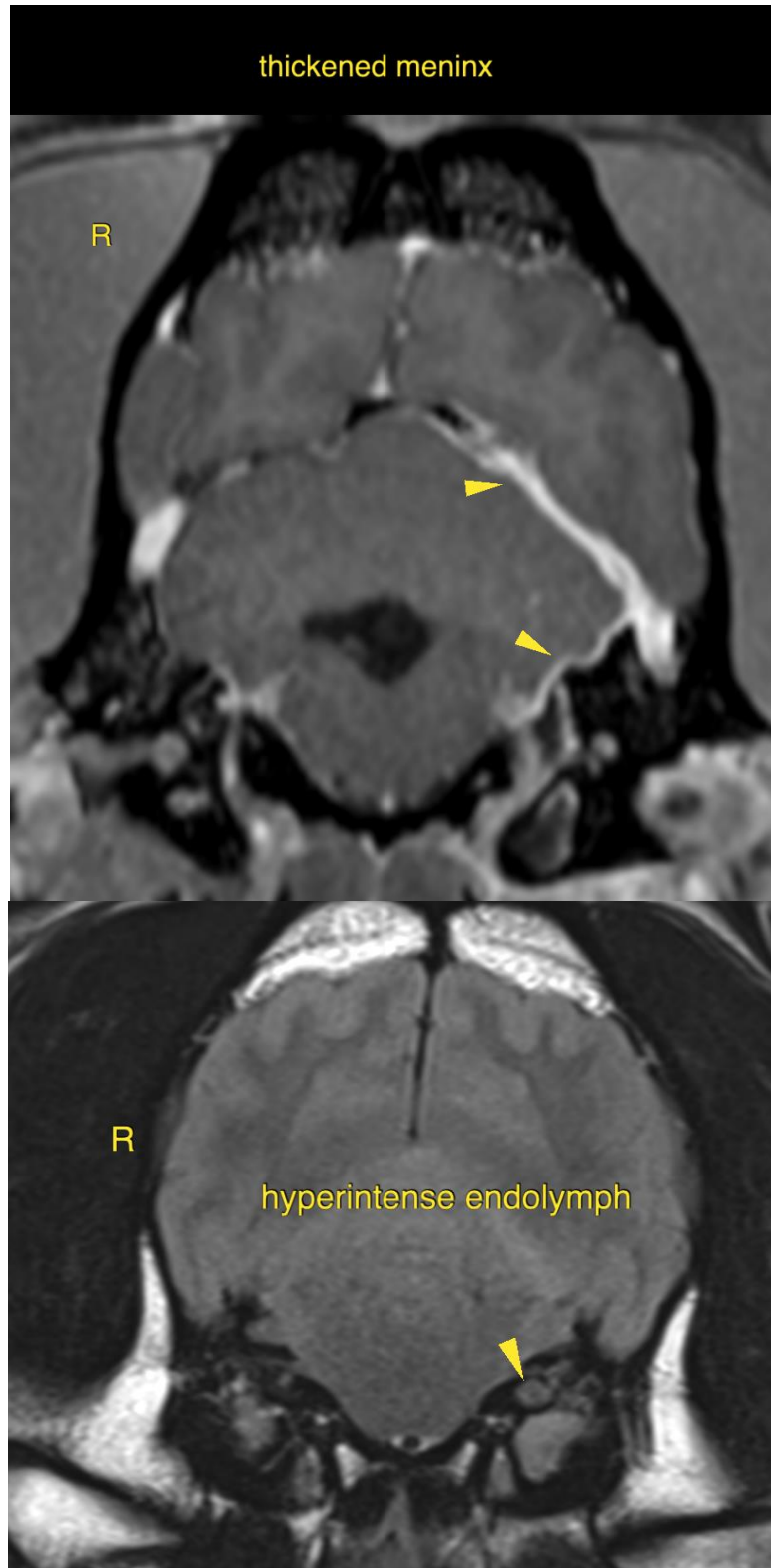Dr. Greg Kilburn

INVOICE

51698

DATE

4-22-22





PATIENT

Chewy Martin

SPECIES

Dog

The information and recommendations provided are based on the images presented by the referring veterinarian/sonographer. No evaluation can be communicated regarding pathology that was not visible in the image/video clips provided.

BREED

Frenchie

Thank you for this referral. If the clinical or image interpretation does not parallel your findings or if I can be of any further assistance please contact me.

Sebastian Schaub, Sebastian Schaub, DVM, Dr. med. vet. DipECVDI
sebast.schaub@gmail.com

SEX

Male

AGE

5 Years

INTERPRETED BY

Sebastian Schaub, DVM
Dr. med. vet. DipECVDI

HOSPITAL NAME

Animal Health
Partners

REFERRING VET

Dr. Greg Kilburn

INVOICE

51698

DATE

4-22-22