

PATIENT

Beau Ang

SPECIES

Canine

BREED

Mixed

SEX

MN

AGE

6

WEIGHT

35.7

INTERPRETED BY

Sebastian Schaub, DVM
Dr. med. vet.
DipECVDI

IMAGING PERFORMED BY

David

HOSPITAL NAME

Animal Surgical Center
- Oceanside

REFERRING VET

Short

INVOICE

74700

DATE

4-21-26

PRESENTING CLINICAL SIGNS

Alert/appropriate, no CP or CN deficits, wide based gait pelvic limbs
Ambulatory x 4, normal musculature, tail dropped and flaccid
suspect neuropathy (L-S versus caudal)- rule out disc compression versus other

COMPUTED TOMOGRAPHY OF THE THORACIC & LUMBAR SPINE

A high resolution plain CT study of the thoracic and lumbar spine is provided for review. In the myelogram, no contrast media is detected in the subarachnoid nor epidural space.

COMPUTED TOMOGRAPHIC FINDINGS

L1 presents a foreshortened rib bilaterally.

The most cranial segment of the thoracic spine is cropped by the field of view.

Level with the intervertebral disc spaces T11/T12, L2/L3, L5/L6, L6/L7 and L7/S1 mild hyperattenuating material is appreciated in the ventral aspect of the vertebral canal, occupying approximately up to 10% of the cross-sectional area of the vertebral canal at the same level.

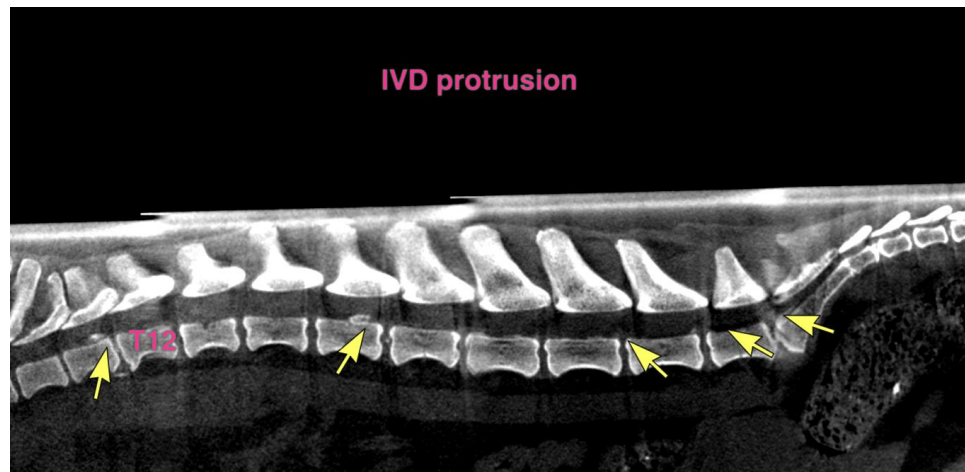
The vertebral endplates T10/T11 to T12/T13 present ventral spondylosis formation.

COMPUTED TOMOGRAPHIC DIAGNOSIS

- Intervertebral disc herniation T11/T12, L2/L3, L5/L6, L6/L7 and L7/S1 without compressive myelopathy
- Thoracolumbar transitional vertebra
- Spondylosis deformans caudal thoracic spine

INTERPRETATION OF THE FINDINGS & FURTHER RECOMMENDATIONS

The CT study reveals no clinically relevant abnormalities and an underlying cause for the described clinical signs cannot be specified.





PATIENT

Beau Ang

The information and recommendations provided are based on the images presented by the referring veterinarian/sonographer. No evaluation can be communicated regarding pathology that was not visible in the image/video clips provided.

SPECIES

Canine

Thank you for this referral. If the clinical or image interpretation does not parallel your findings or if I can be of any further assistance please contact me.

BREED

Mixed

Sebastian Schaub, Sebastian Schaub, DVM, Dr. med. vet. DipECVDI

info@sonopath.com

SEX

MN

AGE

6

WEIGHT

35.7

INTERPRETED BY

Sebastian Schaub, DVM
Dr. med. vet.
DipECVDI

IMAGING PERFORMED BY

David

HOSPITAL NAME

Animal Surgical Center
- Oceanside

REFERRING VET

Short

INVOICE

74700

DATE

4-21-26