



PATIENT PRESENTING CLINICAL SIGNS

Wilson Miliken Non weight bearing lameness RR for 2 months. Progressively worsening. Had a plate and pin for a fracture repair as a puppy

SPECIES RADIOGRAPHIC STUDY OF THE RIGHT FEMUR

Canine A consecutive set of radiographs of the right femur, dated 9/3/22 and 4/21/22, is provided for review.

BREED RADIOGRAPHIC FINDINGS

Australian Shepard 3/9/22

A surgical plate is seen at the lateral aspect of the right femoral diaphysis as well as an intramedullary pin in the femoral diaphysis – no abnormalities of the implants are appreciated (no radiolucent zone). The distal third of the right femoral diaphysis presents a mild caudal convex bulging of the cortex with smooth margins. At the craniodistal aspect of the right femoral diaphysis, mild immature periosteal new bone formation is appreciated.

SEX

MN

AGE

8

4/21/22

Progressive decreased volume of the soft tissue shadow of the musculature of the right hind limb is appreciated. Along the distal segment of the diaphysis of the right femur, progressive palisading periosteal new bone formation is seen. There is evidence of lysis of moth eaten osteolytic lesions of the cranial and caudal cortex of the right femur.

INTERPRETED BY

Sebastian Schaub, DVM
Dr. med. vet. DipECVDI

RADIOGRAPHIC DIAGNOSIS

- Monostotic aggressive predominantly mild osteoproliferative lesion right distal femur

HOSPITAL NAME

Heartland Pet Hospital

INTERPRETATION OF THE FINDINGS & FURTHER RECOMMENDATIONS

The progressive aggressive periosteal new bone formation is highly concerning for implant induced osteosarcoma. No overt signs for implant infection are appreciated. Recommend FNA sampling ± bone biopsy to confirm the diagnosis.

REFERRING VET

Andrew Kliewer

INVOICE

51674

DATE

4-21-22



PATIENT

Wilson Miliken

SPECIES

Canine

BREED

Australian Shepard

SEX

MN

AGE

8

INTERPRETED BY

Sebastian Schaub, DVM
Dr. med. vet. DipECVDI

HOSPITAL NAME

Heartland Pet
Hospital

REFERRING VET

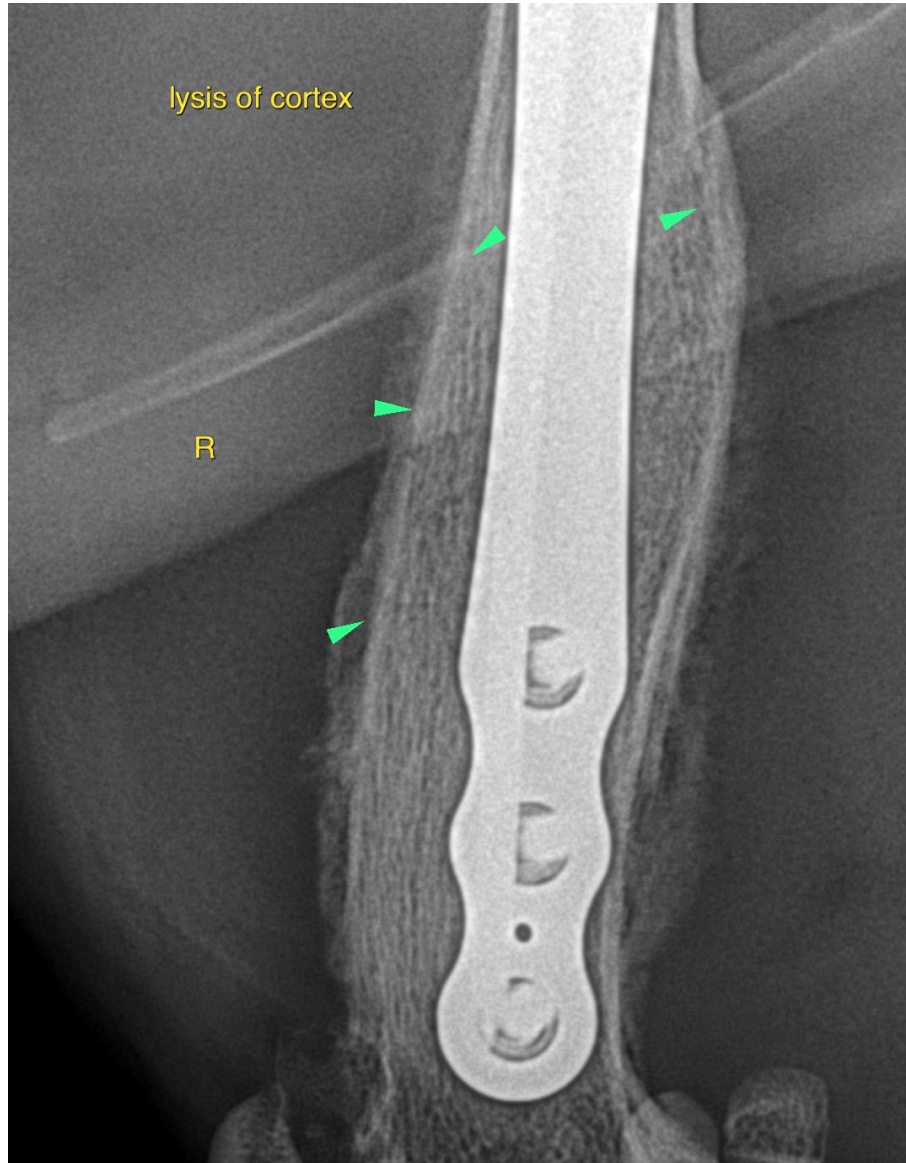
Andrew Kliewer

INVOICE

51674

DATE

4-21-22





PATIENT

Wilson Miliken

SPECIES

Canine

BREED

Australian Shepard

SEX

MN

AGE

8

INTERPRETED BY

Sebastian Schaub, DVM
Dr. med. vet. DipECVDI

HOSPITAL NAME

Heartland Pet
Hospital

REFERRING VET

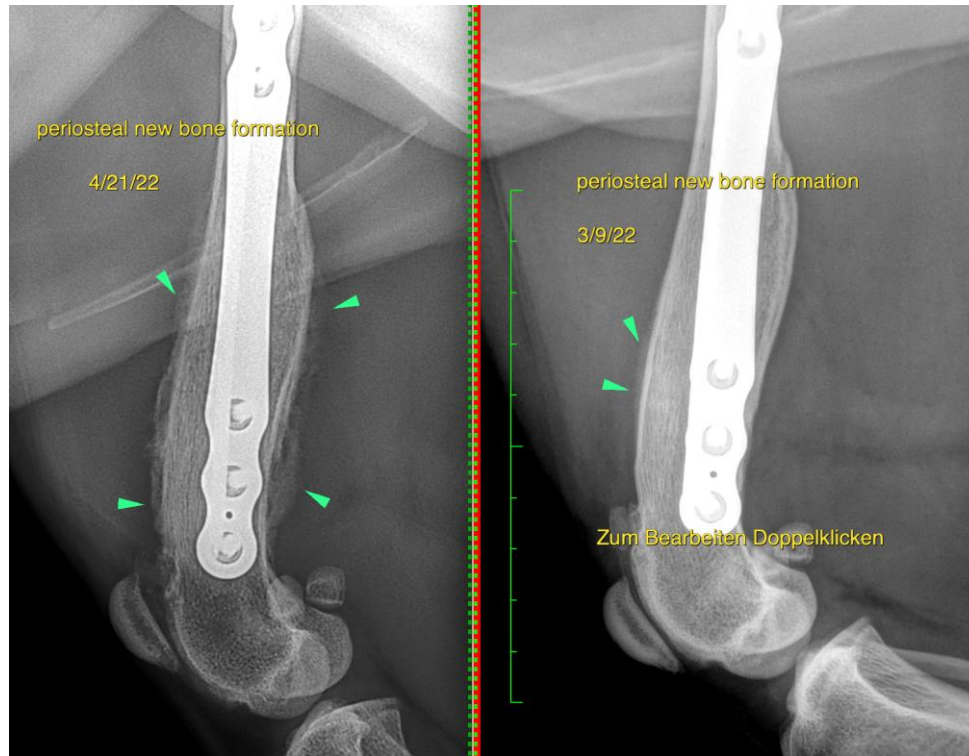
Andrew Kliewer

INVOICE

51674

DATE

4-21-22



The information and recommendations provided are based on the images presented by the referring veterinarian/sonographer. No evaluation can be communicated regarding pathology that was not visible in the image/video clips provided.

Thank you for this referral. If the clinical or image interpretation does not parallel your findings or if I can be of any further assistance please contact me.

Sebastian Schaub, Sebastian Schaub, DVM, Dr. med. vet. DipECVDI
sebast.schaub@gmail.com