



PATIENT PRESENTING CLINICAL SIGNS

Wesley Mark
 Oral melanoma right mandible. CT for staging and surgical planning.
 Abnormal PE/Chem/CBC/UA Results: Oral cavity: 2.4 cm right mid mandible mass

SPECIES COMPUTED TOMOGRAPHY OF THE SKULL & THORAX

Canine
 A pre- and post-contrast CT study of the skull and thorax in a bone, lung and soft tissue reconstruction are provided for review.

COMPUTED TOMOGRAPHIC FINDINGS

Skull

Border Collie
 The tooth elements 101 and 102 are absent. At the buccal aspect of triadan 407&408, a broad based gingival soft tissue attenuating and heterogeneous mild contrast enhancing mass is visible, measuring 1.5 x 2.0 x 2.7 cm in size. The alveolar bone level with the gingival mass presents a smooth concave depression of the osseous surface.

SEX

MN
 The nasal cavity presents the expected aerated spaces between thin & even conchae and turbinates with smooth mucosal lining.

AGE

10 Years
 Both temporomandibular joints present congruent joint spaces with even subchondral bone surfaces and are considered within normal limits.

INTERPRETED BY

Sebastian Schaub, DVM
 Dr. med. vet. DipECVDI

Both tympanic bullae are aerated, the mucosal lining is not seen, the bony wall is smooth and thin. The external ear canals are within normal limits.

The brain presents no deviation from normal anatomy and symmetry. The brain parenchyma is homogeneous and within normal limits for attenuation and distribution of contrast enhancement. The ventricular system is non-dilated and symmetric.

HOSPITAL NAME

Animal Health
 Partners

The submandibular and medial retropharyngeal lymph nodes are small and elongated with a normal short-to-long-axis-ratio is < 0.5, the attenuation and contrast enhancement pattern is uniform.

Thorax

The bony and surrounding soft tissue structures are within normal limits.

REFERRING VET

Jérôme Gagnon,
 DVM, DACVIM
 (Oncology)

The sternal, cranial mediastinal and tracheobronchial lymph nodes are small elongated with a normal short-to-long-axis-ratio is < 0.5, the attenuation and contrast enhancement pattern is uniform and considered within normal limits.

The cardiovascular structures including the pulmonary vasculature are within normal limits.

INVOICE

51660
 The lung parenchyma presents the expected architecture and attenuation behavior.

Small incidental gas pockets are seen within the esophageal lumen, there is no evidence of abnormal dilation.

DATE

4-21-22



PATIENT

Wesley Mark

SPECIES

Canine

BREED

Border Collie

SEX

MN

AGE

10 Years

INTERPRETED BY

Sebastian Schaub, DVM
Dr. med. vet. DipECVDI

HOSPITAL NAME

Animal Health
Partners

REFERRING VET

Jérôme Gagnon,
DVM, DACVIM
(Oncology)

INVOICE

51660

DATE

4-21-22

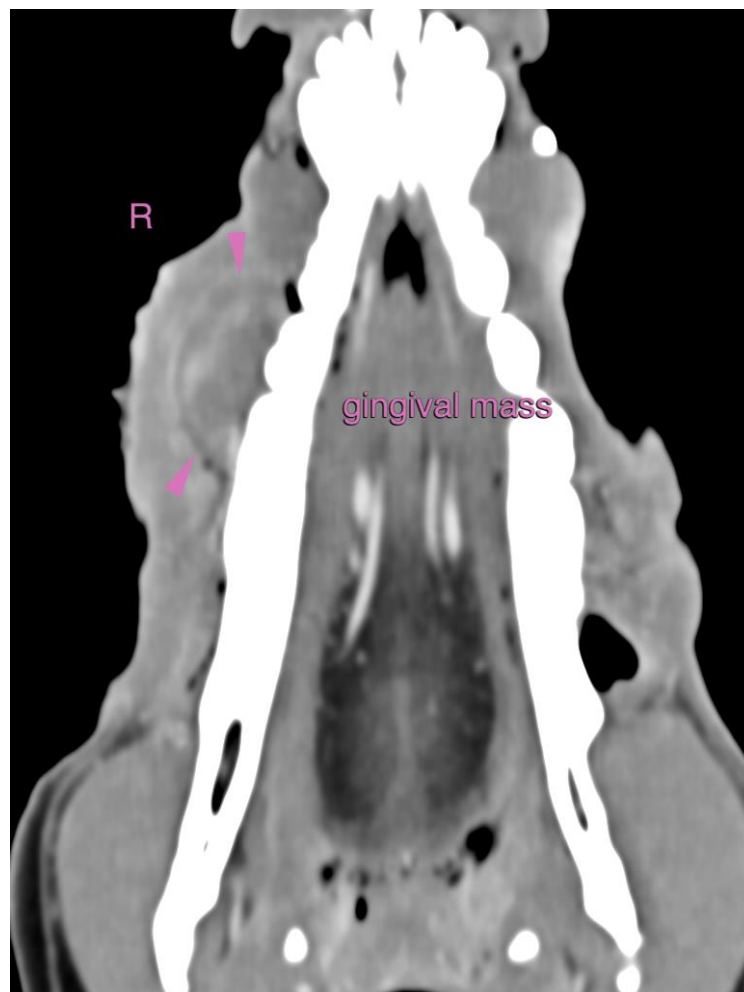
COMPUTED TOMOGRAPHIC DIAGNOSIS

- Gingival mass right body of mandible, level with triadan 407&408 with pressure erosion of the alveolar bone at the same level
- Absent triadan 101 and 102
- Structural normal thorax, no evidence of pulmonary metastatic disease

INTERPRETATION OF THE FINDINGS & FURTHER RECOMMENDATIONS

The gingival mass of the right mandible is fitting the history of oral melanoma. There is no evidence of aggressive osteolysis but pressure erosion of the mandible at the same level. Complete surgical excision by central hemimandibulectomy appears feasible – osteotomy lines should be mesial to triadan 406 and at least distal to triadan 408/better distal to triadan 409.

Consider complementing full tumor staging by FNA sampling of the regional lymph nodes.





PATIENT

Wesley Mark

SPECIES

Canine

BREED

Border Collie

SEX

MN

AGE

10 Years

INTERPRETED BY

Sebastian Schaub, DVM
Dr. med. vet. DipECVDI

HOSPITAL NAME

Animal Health
Partners

REFERRING VET

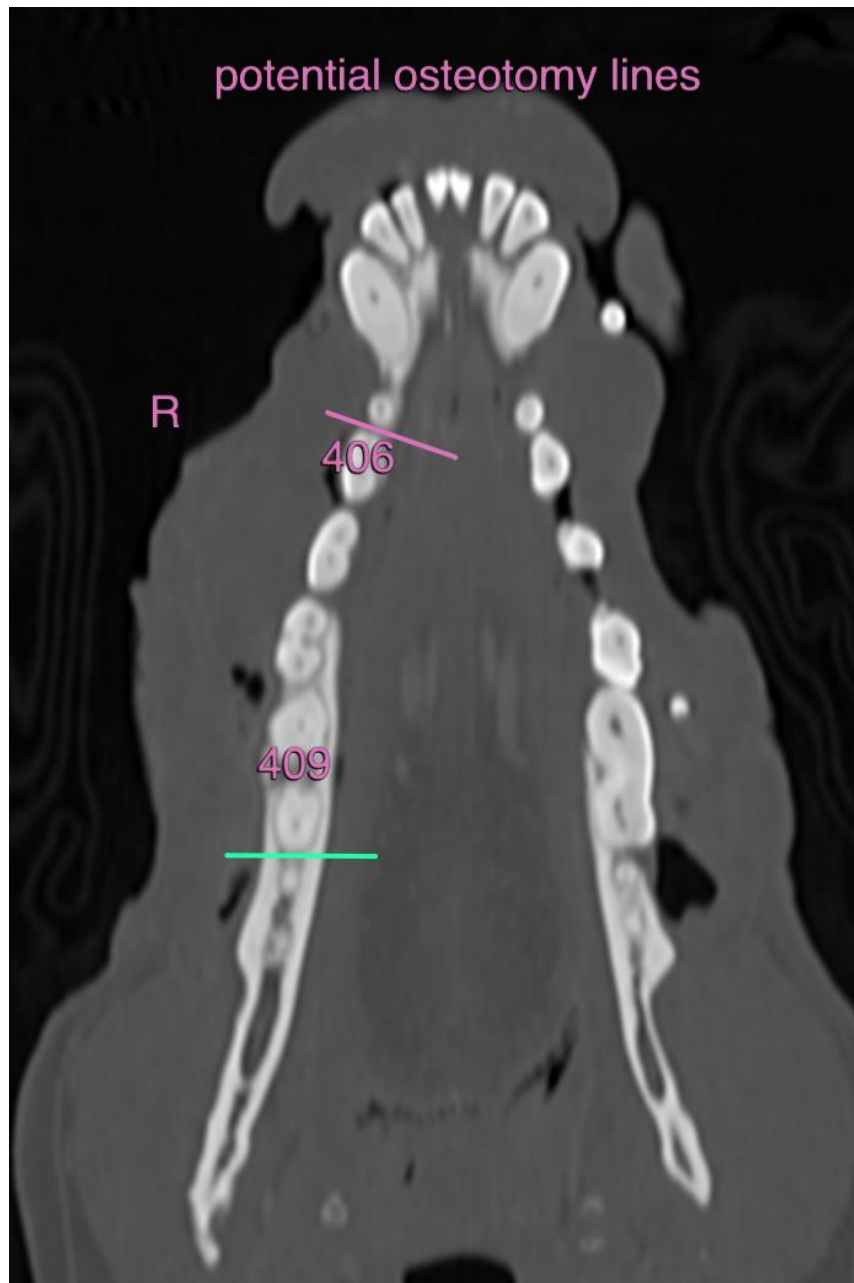Jérôme Gagnon,
DVM, DACVIM
(Oncology)

INVOICE

51660

DATE

4-21-22





PATIENT

Wesley Mark

SPECIES

Canine

BREED

Border Collie

SEX

MN

AGE

10 Years

INTERPRETED BY

Sebastian Schaub, DVM
Dr. med. vet. DipECVDI

HOSPITAL NAME

Animal Health
Partners

REFERRING VET

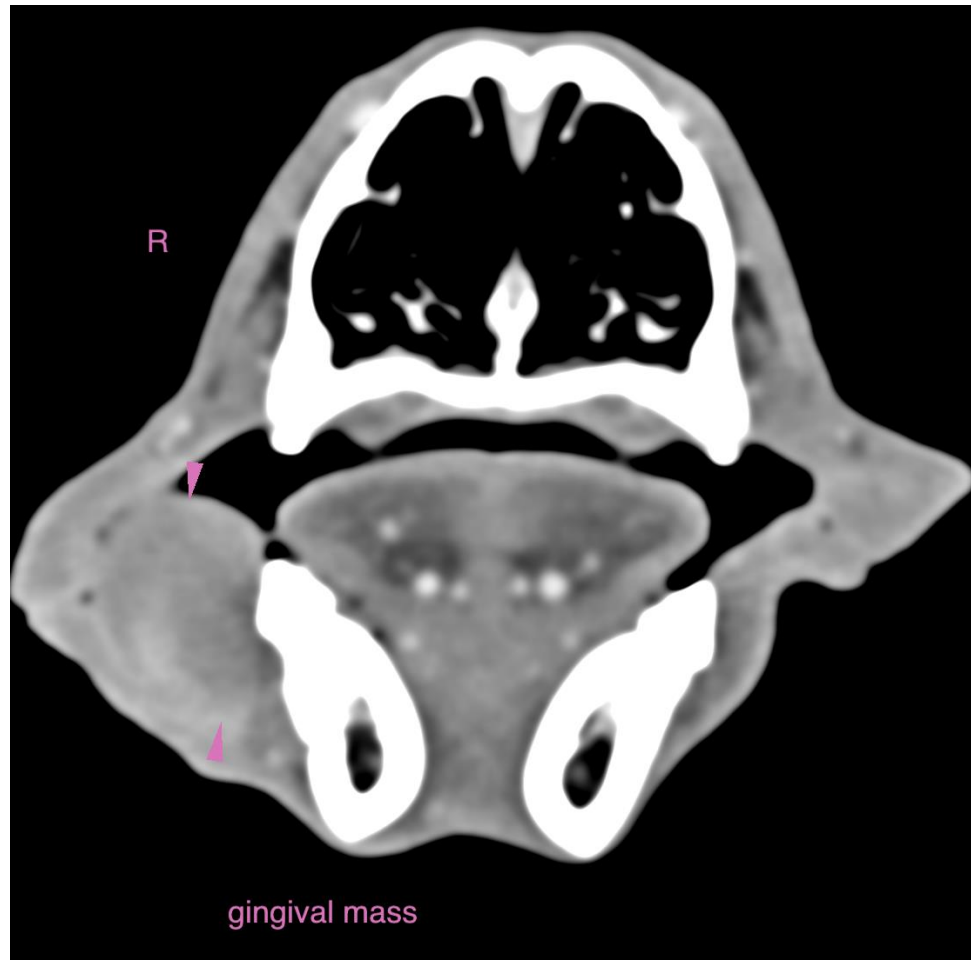Jérôme Gagnon,
DVM, DACVIM
(Oncology)

INVOICE

51660

DATE

4-21-22



The information and recommendations provided are based on the images presented by the referring veterinarian/sonographer. No evaluation can be communicated regarding pathology that was not visible in the image/video clips provided.

Thank you for this referral. If the clinical or image interpretation does not parallel your findings or if I can be of any further assistance please contact me.

Sebastian Schaub, Sebastian Schaub, DVM, Dr. med. vet. DipECVDI
sebast.schaub@gmail.com