

**PATIENT PRESENTING CLINICAL SIGNS**

Smuffy Saad Abdominal ultrasound revealed an irregular masslike appearance within the caudal abdomen.

COMPUTED TOMOGRAPHY OF THE ABDOMEN

SPECIES A high resolution pre- and post-contrast CT study of the abdomen is provided for review.

Feline **COMPUTED TOMOGRAPHIC FINDINGS**

The peritoneal fat in the caudal abdomen, level with the urinary bladder/bladder neck presents mild to moderate fat-stranding. A small amount of free peritoneal gas is seen in the right caudal abdomen.

BREED

DMH In the right aspect of the pelvic canal, an ill-defined soft tissue attenuating swelling with interspersed gas bubbles is visible. The rectum is deviated to the left by the mass effect.

SEX

Both kidneys present within normal limits for size, shape and organ architecture. After contrast administration a bilaterally symmetric and uniform nephro- and pyelogram is noted.

Neutered Male

The adrenal glands are within normal limits for size, shape and organ architecture.

AGE

Both liver and spleen present with normal shape, even surface, uniformly attenuating parenchyma and homogeneous contrast enhancement, unremarkable.

5 Years

The pancreas is evenly contoured, the pancreatic parenchyma is homogeneous and presents uniform contrast enhancement.

The position, delineation, wall and content of the gastrointestinal tract are considered within normal limits throughout.

INTERPRETED BY

The colonic lymph nodes are prominent.

Sebastian Schaub, DVM
Dr. med. vet. DipECVDI

The vertebral endplates of the lumbosacral junction present moderate spondylosis formation.

HOSPITAL NAME**COMPUTED TOMOGRAPHIC DIAGNOSIS**

Mobile Pet Imaging

- Septic peritonitis caudal abdomen
- Soft tissue swelling right aspect pelvic canal with trapped gas
- Lymphadenopathy colonic lymph node

REFERRING VET**INTERPRETATION OF THE FINDINGS & FURTHER RECOMMENDATIONS**

Meaux

The CT findings indicate a septic peritonitis, possibly due to an abscess/granuloma in the pelvic canal. An underlying cause cannot be specified (e.g. migrating foreign body, rectal perforation). Diagnostic laparotomy is recommended.

INVOICE

Secondary reactive hyperplasia of the lymph nodes along the descending colon.

51675

DATE

4-21-22



PATIENT

Smuffy Saad

SPECIES

Feline

BREED

DMH

SEX

Neutered Male

AGE

5 Years

INTERPRETED BY

Sebastian Schaub, DVM
Dr. med. vet. DipECVDI

HOSPITAL NAME

Mobile Pet Imaging

REFERRING VET

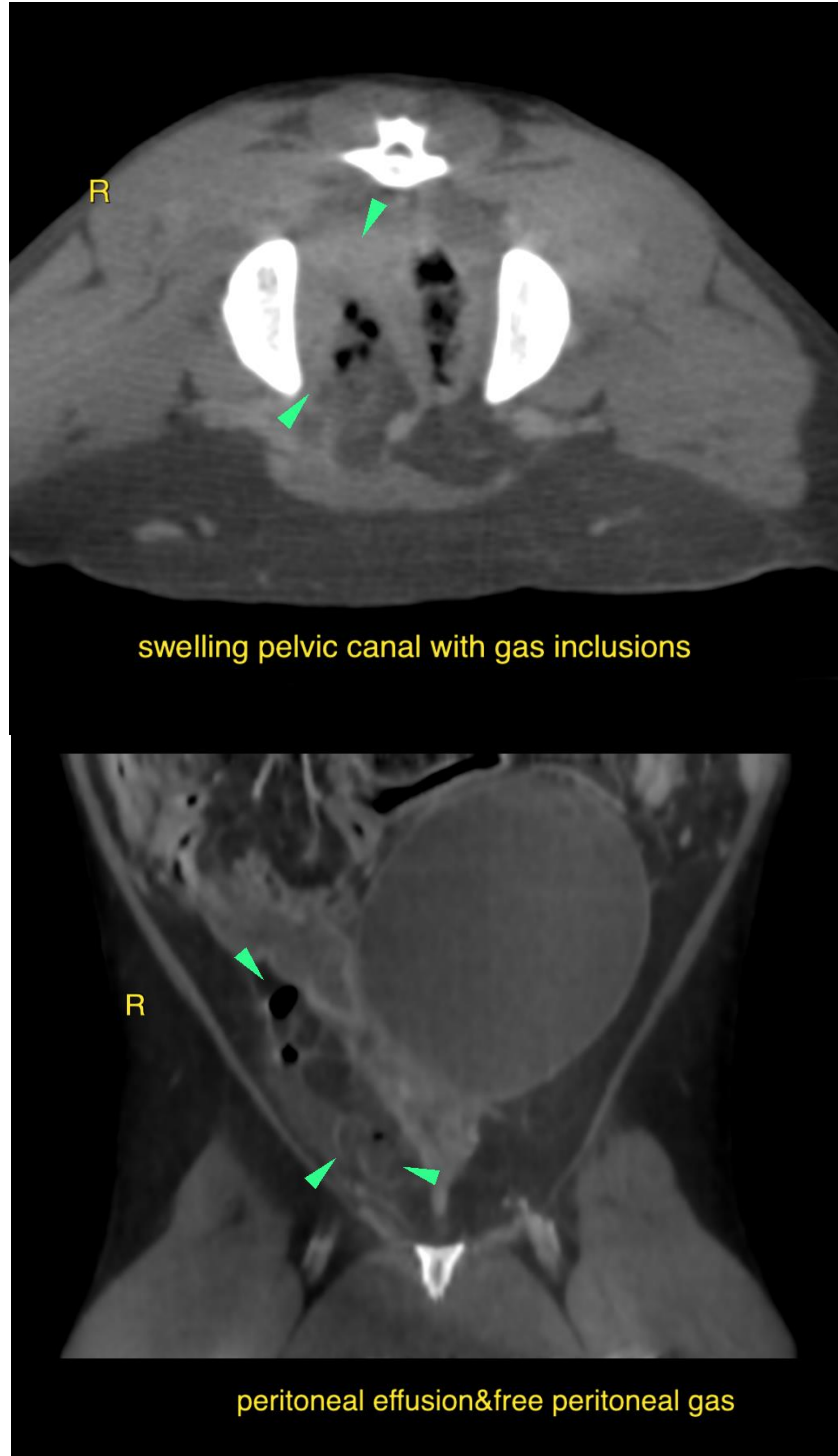
Meaux

INVOICE

51675

DATE

4-21-22



swelling pelvic canal with gas inclusions

peritoneal effusion&free peritoneal gas



PATIENT

Smuffy Saad **The information and recommendations provided are based on the images presented by the referring veterinarian/sonographer. No evaluation can be communicated regarding pathology that was not visible in the image/video clips provided.**

SPECIES

Feline

Thank you for this referral. If the clinical or image interpretation does not parallel your findings or if I can be of any further assistance please contact me.

Sebastian Schaub, Sebastian Schaub, DVM, Dr. med. vet. DipECVDI
sebast.schaub@gmail.com

BREED

DMH

SEX

Neutered Male

AGE

5 Years

INTERPRETED BY

Sebastian Schaub, DVM
Dr. med. vet. DipECVDI

HOSPITAL NAME

Mobile Pet Imaging

REFERRING VET

Meaux

INVOICE

51675

DATE

4-21-22