



PATIENT

Symone Hartzell

SPECIES

Feline

BREED

Domestic Shorthair

SEX

Female Spayed

AGE

10.11Y

WEIGHT

11.06lbs

INTERPRETED BY

Sebastian Schaub, DVM
Dr. med. vet.
DipECVDI

IMAGING PERFORMED BY

Renee Ziegler-Post

HOSPITAL NAME

For Cats Only
Veterinary Clinic

REFERRING VET

Renee Ziegler-Post

INVOICE

74691

DATE

4-20-26

PRESENTING CLINICAL SIGNS

Right side Unilateral ocular and nasal discharge.

RADIOGRAPHIC STUDY OF THE SKULL

Radiographs of the skull in two image planes are provided for review.

RADIOGRAPHIC FINDINGS

The right nasal cavity presents a generalized decreased radiopacity with loss of the striation of the conchal structures. Along the dorsal aspect of the nasal bone, focal solid periosteal new bone formation is appreciated.

Multiple teeth are absent.

The tympanic bullae are aerated and present a smooth and thin wall

RADIOGRAPHIC DIAGNOSIS

- Decreased radiopacity right nasal cavity
- Periosteal new bone formation along dorsal osseous lining of the nose

INTERPRETATION OF THE FINDINGS & FURTHER RECOMMENDATIONS

The findings are suggestive for right sided destructive rhinitis – commonly primary viral ± bacterial or mycotic superinfection. A potential would be an increased radiopacity of the left nasal cavity – but I suppose this is subjective as the striation of the conchal structures is maintained. I do not see signs of a nasal soft tissue mass nor nasopharyngeal polyp formation.

The periosteal new bone formation along the dorsal aspect of the nose can be a sequela to rhinitis and accompanying osteitis.

A CT study can be used for confirmation and to rule out underlying aggressive nasal disease entirely.



PATIENT

Symone Hartzell

SPECIES

Feline

BREED

Domestic Shorthair

SEX

Female Spayed

AGE

10.11Y

WEIGHT

11.06lbs

INTERPRETED BY

Sebastian Schaub, DVM
Dr. med. vet.
DipECVDI

IMAGING PERFORMED BY

Renee Ziegler-Post

HOSPITAL NAME

For Cats Only
Veterinary Clinic

REFERRING VET

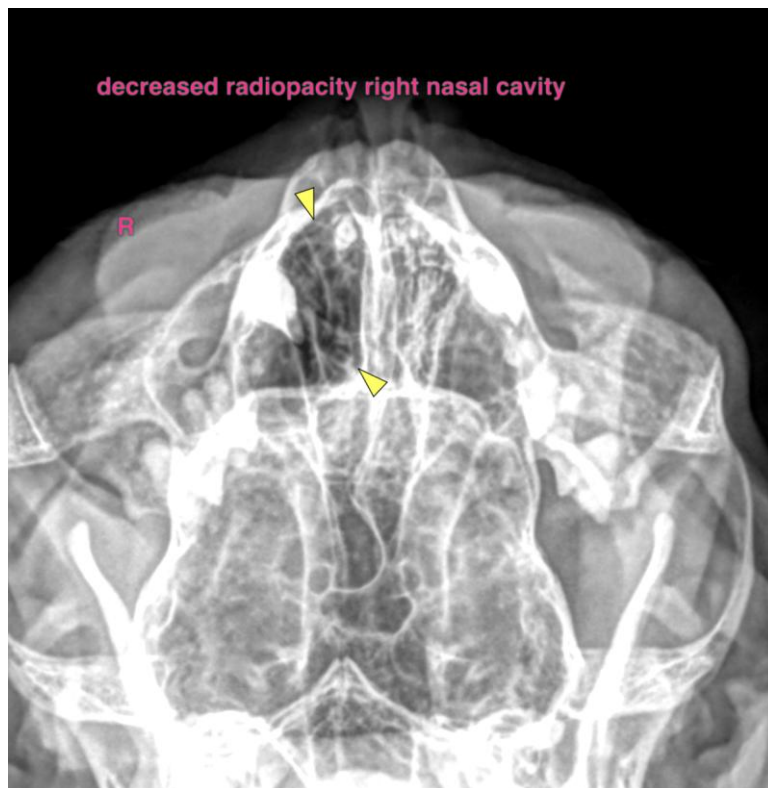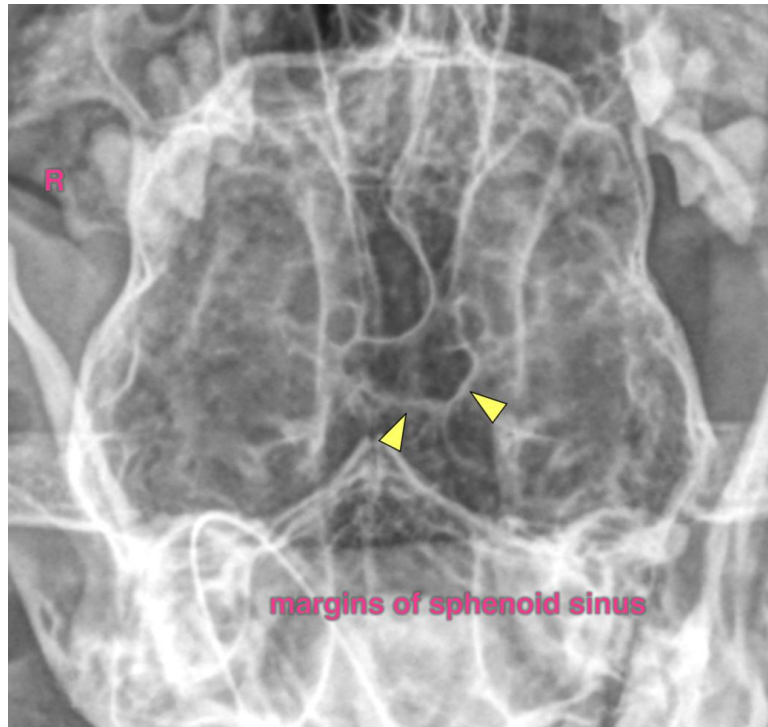
Renee Ziegler-Post

INVOICE

74691

DATE

4-20-26





PATIENT

Symone Hartzell

SPECIES

Feline

BREED

Domestic Shorthair

SEX

Female Spayed

AGE

10.11Y

WEIGHT

11.06lbs

INTERPRETED BY

Sebastian Schaub, DVM
Dr. med. vet.
DipECVDI

IMAGING PERFORMED BY

Renee Ziegler-Post

HOSPITAL NAME

For Cats Only
Veterinary Clinic

REFERRING VET

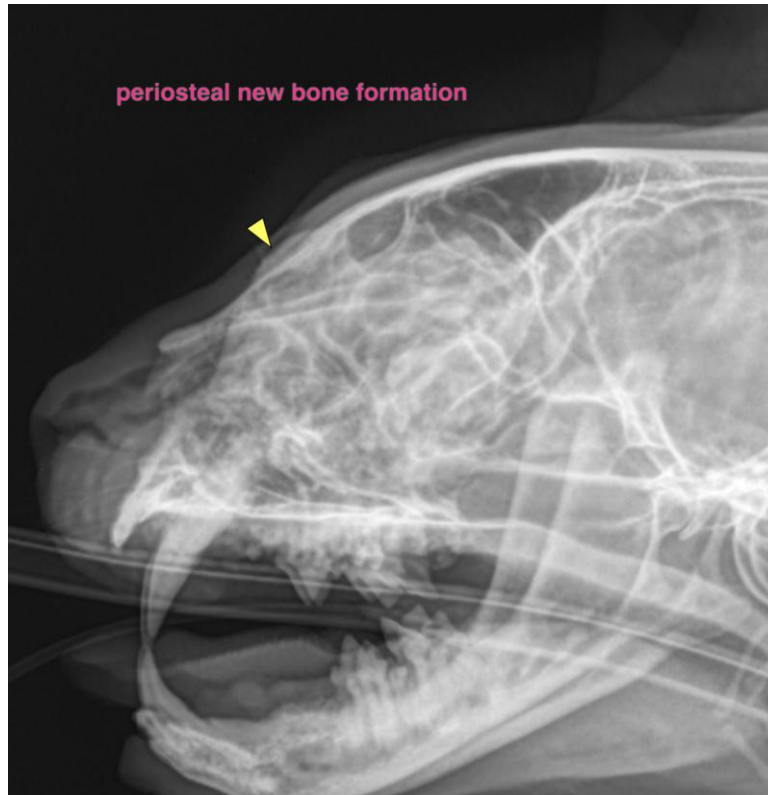
Renee Ziegler-Post

INVOICE

74691

DATE

4-20-26



The information and recommendations provided are based on the images presented by the referring veterinarian/sonographer. No evaluation can be communicated regarding pathology that was not visible in the image/video clips provided.

Thank you for this referral. If the clinical or image interpretation does not parallel your findings or if I can be of any further assistance please contact me.

Sebastian Schaub, Sebastian Schaub, DVM, Dr. med. vet. DipECVDI
info@sonopath.com