



PATIENT

Cooper Connolly

SPECIES

Canine

BREED

Mixed Lg.

SEX

Male Neutered

AGE

9Y

WEIGHT

69lbs

INTERPRETED BY

Sebastian Schaub, DVM
Dr. med. vet.
DipECVDI

IMAGING PERFORMED BY

Dr. Abina Glennon

HOSPITAL NAME

New Bridge Veterinary
Practice

REFERRING VET

Dr. Abina Glennon

INVOICE

74664

DATE

4-20-26

PRESENTING CLINICAL SIGNS

Limping on both hind legs. Left worse than right.

RADIOGRAPHIC STUDY OF THE PELVIS

Radiographs of the pelvis in two orthogonal image planes are provided for review.

RADIOGRAPHIC FINDINGS

The periarticular bones of both coxofemoral joints present advanced osteophyte new bone formation and the femoral heads are distorted. The acetabular groove bilaterally is shallow, and the center of the femoral heads is lateral to the dorsal acetabular rim. The joint space of the coxofemoral joints is incongruent.

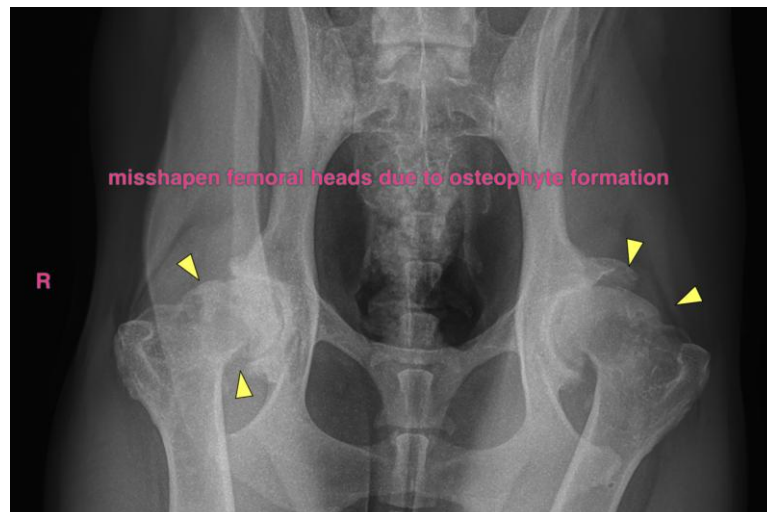
The remainder of the osseous and surrounding soft tissue structures of the pelvis are unremarkable.

RADIOGRAPHIC DIAGNOSIS

- Advanced osteoarthritis of both coxofemoral joints due to severe hip dysplasia

INTERPRETATION OF THE FINDINGS & FURTHER RECOMMENDATIONS

The degenerative joint disease of both coxofemoral joints secondary to hip dysplasia is a likely explanation for the hind limb lameness.



The information and recommendations provided are based on the images presented by the referring veterinarian/sonographer. No evaluation can be communicated regarding pathology that was not visible in the image/video clips provided.

Thank you for this referral. If the clinical or image interpretation does not parallel your findings or if I can be of any further assistance please contact me.

Sebastian Schaub, Sebastian Schaub, DVM, Dr. med. vet. DipECVDI
info@sonopath.com