



PATIENT

Bert Downey

SPECIES

Feline

BREED

DSH

SEX

Male N

AGE

4Y

WEIGHT

25.28lbs

INTERPRETED BY

Sebastian Schaub, DVM
Dr. med. vet.
DipECVDI

IMAGING PERFORMED BY

Cottage Grove
Veterinary Clinic

HOSPITAL NAME

Cottage Grove
Veterinary Clinic

REFERRING VET

Damewood

INVOICE

74660

DATE

4-20-26

PRESENTING CLINICAL SIGNS

Vomiting food and water for 1 week

RADIOGRAPHIC STUDY OF THE ABDOMEN

Radiographs of the abdomen in two orthogonal image planes are provided for review.

RADIOGRAPHIC FINDINGS

The surrounding bony structures are within normal limits.

No abnormalities of the extraabdominal soft tissues are noted. The abdominal wall is smooth and thin.

The serosal detail is maintained throughout the peritoneal and retroperitoneal space.

The liver is appropriate in position, size and presents uniform opacity.

The splenic head is in the anticipated position and within normal limits for size and opacity. The splenic body and tail are considered normal for position, size, shape and opacity.

Both kidneys are seen and present mild irregular margins. The urinary bladder is in its anticipated position. No radiopaque calculi are noted throughout the upper and lower urinary tract.

The stomach is in its anticipated position and presents normal content.

The small intestinal loops are of even diameter and non-dilated, a small amount of gas is seen within the small intestinal loops and considered within normal limits.

The colon is seen in the expected position and contains a small amount of fecal material.

RADIOGRAPHIC DIAGNOSIS

- Overall empty gastrointestinal tract
- Chronic nephropathy

INTERPRETATION OF THE FINDINGS & FURTHER RECOMMENDATIONS

The radiographic study reveals no abnormalities that do explain the vomiting. There is no evidence of radiopaque foreign material, abnormal gas pattern or signs for gastrointestinal mechanical obstruction. Rule out gastritis, parasitic infection, dietary indiscretion, pancreatitis, other. If clinical signs are refractory to therapy, recommend follow up radiographs in two orthogonal imaging planes or a complete abdominal ultrasound examination; in some cases, a high ileus may lack classical radiographic signs of mechanical obstruction.



PATIENT

Bert Downey

SPECIES

Feline

BREED

DSH

SEX

Male N

AGE

4Y

WEIGHT

25.28lbs

INTERPRETED BY

Sebastian Schaub, DVM
Dr. med. vet.
DipECVDI

IMAGING PERFORMED BY

Cottage Grove
Veterinary Clinic

HOSPITAL NAME

Cottage Grove
Veterinary Clinic

REFERRING VET

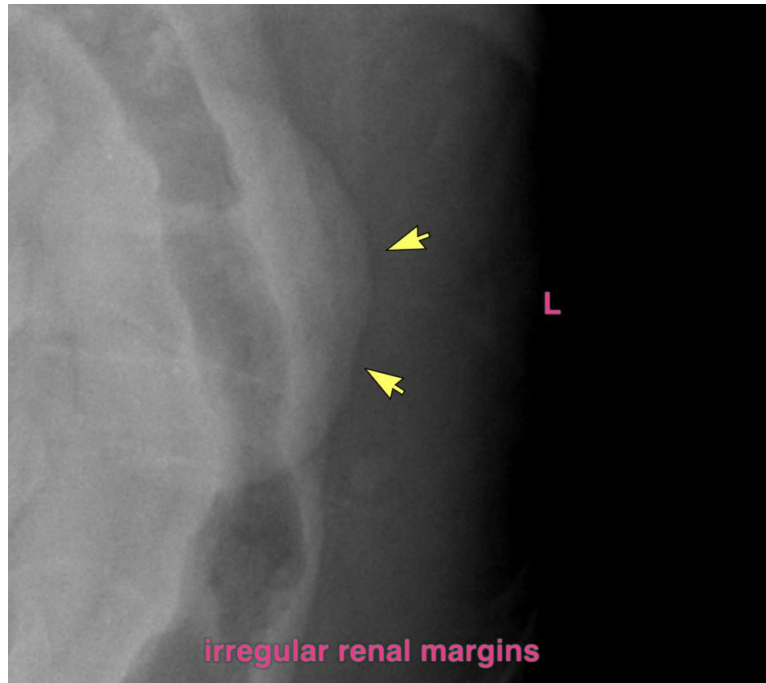
Damewood

INVOICE

74660

DATE

4-20-26



The information and recommendations provided are based on the images presented by the referring veterinarian/sonographer. No evaluation can be communicated regarding pathology that was not visible in the image/video clips provided.

Thank you for this referral. If the clinical or image interpretation does not parallel your findings or if I can be of any further assistance please contact me.

Sebastian Schaub, Sebastian Schaub, DVM, Dr. med. vet. DipECVDI
info@sonopath.com