



PATIENT PRESENTING CLINICAL SIGNS

Sammy Jacobs History: Seizures past 3 weeks. Bit by mother on skull at 3 days of age. Rx: Gabapentin and Diazepam.
Abnormal PE/Chem/CBC/UA Results: ALT 61HIGH 9-43 U/L ALKP 36LOW 92-294 U/L GGT 47HIGH 16-30 U/L TBIL 0.2 0.1-0.3 mg/dL

SPECIES

Porcine

COMPUTED TOMOGRAPHIC STUDY OF THE SKULL & THORAX

A high resolution pre- and post-contrast CT study of the skull and a post-contrast CT study of the thorax are provided for review.

BREED

Miniature Potbellied Pig

COMPUTED TOMOGRAPHIC FINDINGS

Skull

SEX

Electronic side markers are flipped, R is presenting the left side of the patient and vice versa.

Neutered Male

The pictured parts of the dentition are complete and unremarkable in all jaw quadrants.

AGE

2 Years

The left frontal sinus is filled with fluid attenuating material. The frontal bone presents with multiple rounded fracture lines distorting the dorsal osseous lamella of the frontal sinuses/rostral aspect of the calvarium with evidence of perforation of the cranial fossa. Post contrast administration, multiple variable sized (measuring up to 20 mm in diameter, peripherally accentuated contrast enhancing lesions are seen in the frontal lobe of the brain bilaterally. Focal punctuate mineralization of the contrast enhancing lesions is appreciated.

INTERPRETED BY

Sebastian Schaub, DVM
Dr. med. vet.
DipECVDI

Both temporomandibular joints present congruent joint spaces with even subchondral bone surfaces and are considered within normal limits.

Both tympanic bullae are aerated, the mucosal lining is not seen, the bony wall is smooth and thin. The external ear canals are within normal limits.

HOSPITAL NAME

Thorax

Mobile Pet Imaging
CFL

The bony and surrounding soft tissue structures are within normal limits.

REFERRING VET

Borecky

The sternal, cranial mediastinal and tracheobronchial lymph nodes are small elongated with a normal short-to-long-axis-ratio is < 0.5, the attenuation and contrast enhancement pattern is uniform and considered within normal limits.

The cardiovascular structures including the pulmonary vasculature are within normal limits.

INVOICE

14824

The bronchial tree presents with regular branching and tapers uniformly towards the periphery as expected, the bronchial walls are thin and smooth. The bronchus-to-artery ratio is within normal limits. The lung parenchyma presents the expected architecture and attenuation behavior.

DATE

4/20/22

Small incidental gas pockets are seen within the esophageal lumen, there is no evidence of abnormal dilation.



PATIENT COMPUTED TOMOGRAPHIC DIAGNOSIS

Sammy Jacobs

- History of traumatic fractures of the frontal bone with perforation of the cranial fossa
- Multiple intracranial intraaxial asymmetrically distributed contrast enhancing lesions frontal lobe bilaterally with dystrophic mineralization

SPECIES

Porcine

- Left sided sinusitis of the frontal sinus
- Normal thorax

INTERPRETATION OF THE FINDINGS & FURTHER RECOMMENDATIONS

The findings are highly concerning for intraaxial abscess or granuloma (e.g., mycotic) formation in the frontal lobes bilaterally – very likely secondary to the traumatic insult with perforation of the cranial fossa. If applicable, a CSF tap might be used as advanced diagnostic tool. The prognosis is very guarded.

BREED

Miniature Potbellied Pig

SEX

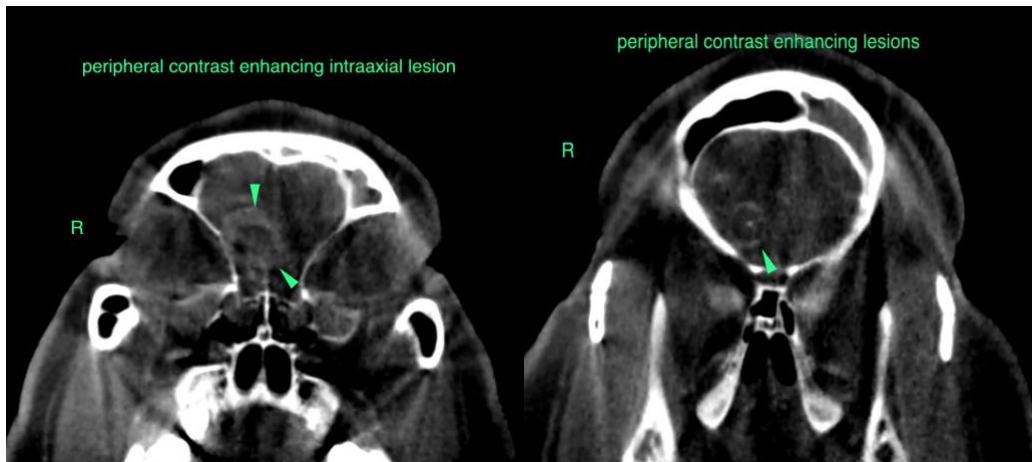
Neutered Male

AGE

2 Years

INTERPRETED BY

Sebastian Schaub, DVM
Dr. med. vet.
DipECVDI



HOSPITAL NAME

Mobile Pet Imaging
CFL

The information and recommendations provided are based on the images presented by the referring veterinarian/sonographer. No evaluation can be communicated regarding pathology that was not visible in the image/video clips provided.

Thank you for this referral. If the clinical or image interpretation does not parallel your findings or if I can be of any further assistance please contact me.

REFERRING VET

Borecky

Sebastian Schaub, Sebastian Schaub, DVM, Dr. med. vet. DipECVDI
sebast.schaub@gmail.com

INVOICE

14824

DATE

4/20/22



PATIENT

Sammy Jacobs

SPECIES

Porcine

BREED

Miniature Potbellied
Pig

SEX

Neutered Male

AGE

2 Years

INTERPRETED BY

Sebastian Schaub, DVM
Dr. med. vet.
DipECVDI

HOSPITAL NAME

Mobile Pet Imaging
CFL

REFERRING VET

Borecky

INVOICE

14824

DATE

4/20/22