



PATIENT PRESENTING CLINICAL SIGNS

Nugget Miller History: Nugget presented for small mass inside of mouth on the inner left side cheek. No Bx taken. RDVM mentioned papilloma. O states mass is among the gum lines. Abnormal PE/Chem/CBC/UA Results:

SPECIES COMPUTED TOMOGRAPHIC STUDY OF THE SKULL & THORAX

Canine A high-resolution post-contrast CT study of the skull and thorax is provided for review.

BREED COMPUTED TOMOGRAPHIC FINDINGS

Golden Retriever **Skull**

SEX The pictured parts of the dentition are complete and unremarkable in all jaw quadrants. At the buccal aspect of triadan 207, a mild irregular shaped, soft tissue attenuating mass is protruding from the gingival lining, measuring approximately 14 x 9 x 12 mm in size; the osseous lining at the same level is smooth and unremarkable.

Male

The nasal cavity presents the expected aerated spaces between thin & even conchae and turbinates with smooth mucosal lining.

AGE

12 Years

Both temporomandibular joints present congruent joint spaces with even subchondral bone surfaces and are considered within normal limits.

INTERPRETED BY

Sebastian Schaub,
DVM Dr. med. vet.
DipECVDI

Both tympanic bullae are aerated, the mucosal lining is not seen, the bony wall is smooth and thin. The external ear canals are mildly narrowed and present a mild irregular epithelial lining. Mild shell-like mineralization of the wall of the external ear canals is appreciated.

The brain presents no deviation from normal anatomy and symmetry. The brain parenchyma is homogeneous and within normal limits for attenuation and distribution of contrast enhancement. The ventricular system is non-dilated and symmetric.

HOSPITAL NAME

Animal Surgical
Center

The submandibular and medial retropharyngeal lymph nodes are small and elongated with a normal short-to-long-axis-ratio is < 0.5, the attenuation and contrast enhancement pattern is uniform.

Thorax

REFERRING VET

Dr. Alberto Lodico

Multifocal moderate spondylosis formation is seen along the thoracic spine.

The sternal, cranial mediastinal and tracheobronchial lymph nodes are small elongated with a normal short-to-long-axis-ratio is < 0.5, the attenuation and contrast enhancement pattern is uniform and considered within normal limits.

INVOICE

14831

The cardiovascular structures including the pulmonary vasculature are within normal limits.

DATE

4/20/22

The bronchial tree presents with regular branching and tapers uniformly towards the periphery as expected, the bronchial walls are thin and smooth. The bronchus-to-artery ratio is within normal limits. The ventral dependent aspects of the lung present regions of dystelectasis. The remainder of the lung parenchyma present the expected architecture and attenuation behavior.



PATIENT

Nugget Miller
 Small incidental gas pockets are seen within the esophageal lumen, there is no evidence of abnormal dilation.

COMPUTED TOMOGRAPHIC DIAGNOSIS

SPECIES

Canine

- Poplypoid gingival mass level triadan 207
- Bilateral otitis externa with mild dystrophic mineralization
- Dystelectasis ventral aspects of the lung due to general anesthesia
- Spondylosis deformans
- No evidence of pulmonary metastatic disease

BREED

Golden Retriever

INTERPRETATION OF THE FINDINGS & FURTHER RECOMMENDATIONS

The findings are fitting the history of a small gingival mass level with triadan 207, without signs of osseous involvement. Potentials include benign fibrous epulis/papilloma or emerging malignant gingival neoplasia (e.g. melanoma, squamous cell carcinoma) – considered less likely due to the lack of aggressive imaging features. Consider excision biopsy for further definition.

SEX

Male

AGE

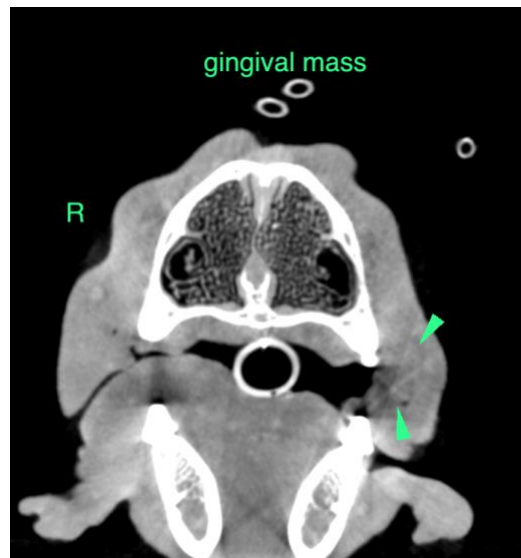
12 Years

INTERPRETED BY

Sebastian Schaub,
 DVM Dr. med. vet.
 DipECVDI

HOSPITAL NAME

Animal Surgical
 Center



REFERRING VET

Dr. Alberto Lodico

The information and recommendations provided are based on the images presented by the referring veterinarian/sonographer. No evaluation can be communicated regarding pathology that was not visible in the image/video clips provided.

Thank you for this referral. If the clinical or image interpretation does not parallel your findings or if I can be of any further assistance please contact me.

INVOICE

14831

Sebastian Schaub, Sebastian Schaub, DVM, Dr. med. vet. DipECVDI
 sebast.schaub@gmail.com

DATE

4/20/22



PATIENT

Nugget Miller

SPECIES

Canine

BREED

Golden Retriever

SEX

Male

AGE

12 Years

INTERPRETED BY

Sebastian Schaub,
DVM Dr. med. vet.
DipECVDI

HOSPITAL NAME

Animal Surgical
Center

REFERRING VET

Dr. Alberto Lodico

INVOICE

14831

DATE

4/20/22