

**PATIENT**

Gus Deelen - Burgees

PRESENTING CLINICAL SIGNS

Gus is a 8-year-old neutered Schnauzer mix who has a history of limping on the front limbs over the last couple of weeks. On physical exam normal range of motion on his front legs was noticed and no pain was elicited upon palpation of his left and right front leg.

SPECIES

Canine

RADIOGRAPHIC STUDY OF THE FRONT LIMBS

A complete set of radiographs of the front limbs is provided for review.

BREEDSchnauzer, Miniature
Mix**RADIOGRAPHIC FINDINGS**

An isolated mineralized body is seen at the distal aspect of the left acromion. A mineralized remnant of the clavicle is seen proximal to the greater tubercle of the humerus bilaterally. Both shoulder joints present smooth osseous margins, without abnormalities of the surrounding soft tissue structures.

SEX

Neutered Male

The periarticular bones of both elbow joints present mild to moderate osteophyte new formation. The contour of the medial coronoid process is ill-defined.

The osseous structures of both carpal joints present smooth osseous margins, unremarkable.

AGE

8

RADIOGRAPHIC DIAGNOSIS

- Mild degenerative osteoarthritis elbow joints bilaterally
- Suspect coronoid disease elbow joints bilaterally
- Isolated ossification center versus metaplasia distal aspect left acromion, incidental
- Normal shoulder joints
- Normal carpal joints

INTERPRETED BYSebastian Schaub, DVM
Dr. med. vet. DipECVDI**INTERPRETATION OF THE FINDINGS & FURTHER RECOMMENDATIONS**

The degenerative changes of both elbow joints can be the sequela to pathology of the medial coronoid process. Recommend rechecking the elbow joints and testing if pain can be elicited by pressure on the medial compartment of the elbow joints. A CT study can be used for further evaluation of the elbow joints.

HOSPITAL NAMEBeaches-Fallingbrook
Veterinary Clinic**REFERRING VET**

Dr Sam Shahsavari

The remainder of both front limbs are within normal limits.

INVOICE

51311

DATE

4-2-22



PATIENT

Gus Deelen - Burgees

SPECIES

Canine

BREED

Schnauzer, Miniature
Mix

SEX

Neutered Male

AGE

8

INTERPRETED BY

Sebastian Schaub, DVM
Dr. med. vet. DipECVDI

HOSPITAL NAME

Beaches-Fallingbrook
Veterinary Clinic

REFERRING VET

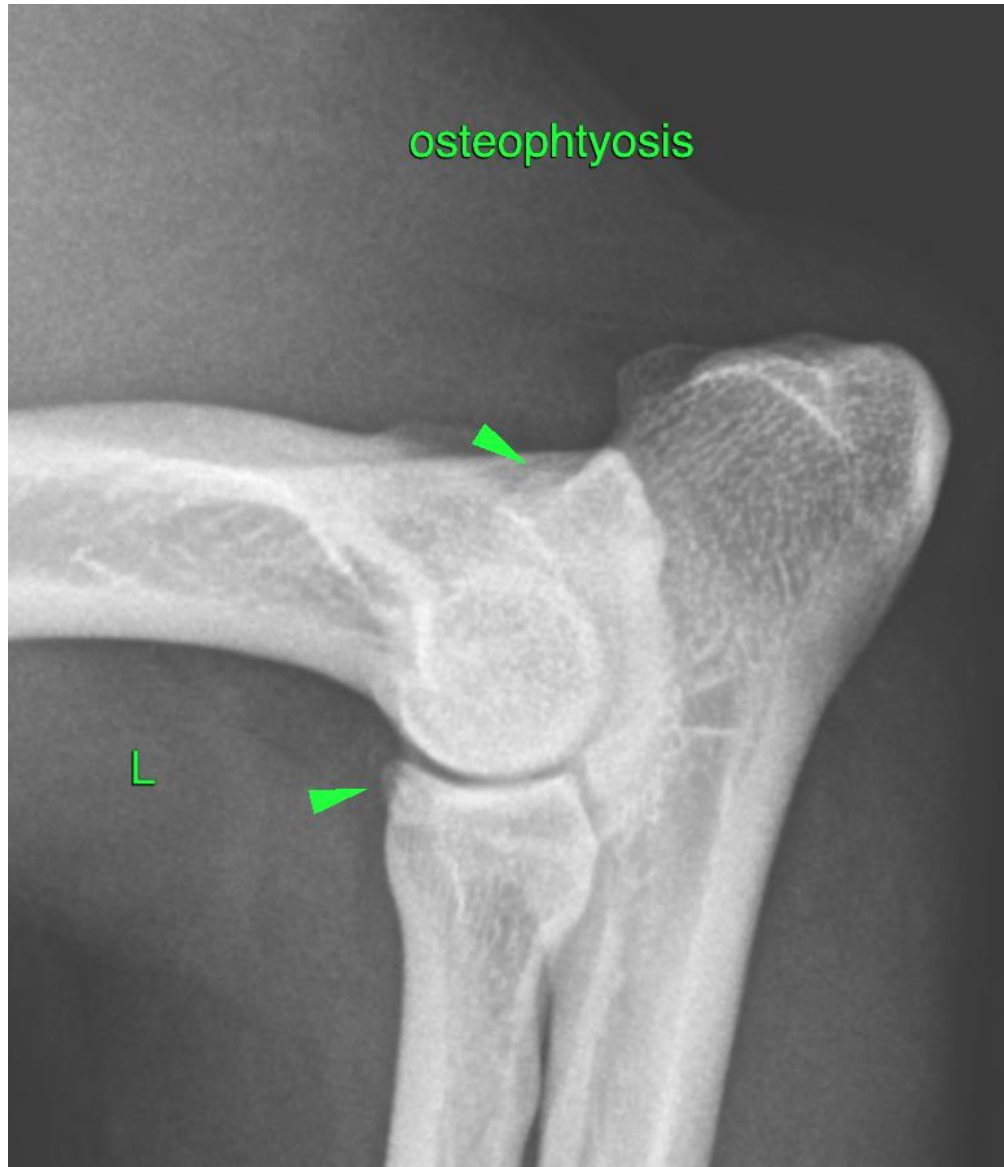
Dr Sam Shahsavari

INVOICE

51311

DATE

4-2-22





PATIENT

Gus Deelen - Burgees

SPECIES

Canine

BREED

Schnauzer, Miniature
Mix

SEX

Neutered Male

AGE

8

INTERPRETED BY

Sebastian Schaub, DVM
Dr. med. vet. DipECVDI

HOSPITAL NAME

Beaches-Fallingbrook
Veterinary Clinic

REFERRING VET

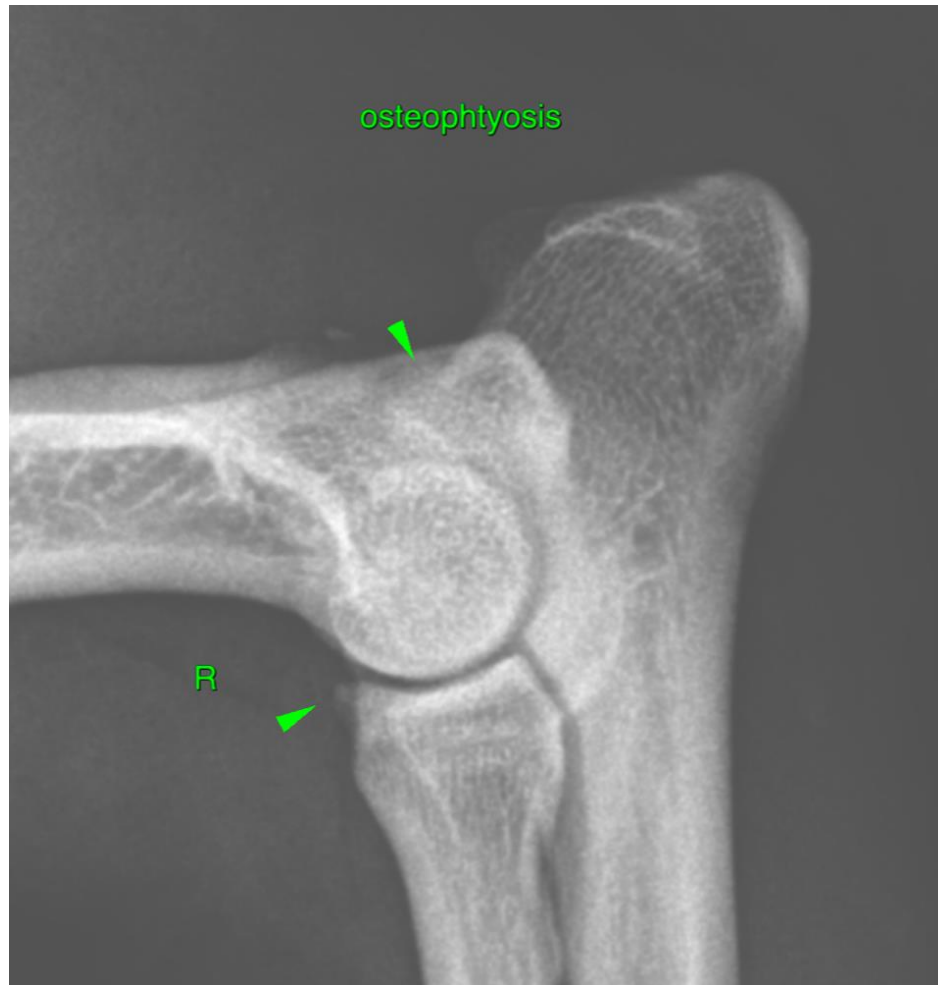Dr Sam Shahsavari

INVOICE

51311

DATE

4-2-22



The information and recommendations provided are based on the images presented by the referring veterinarian/sonographer. No evaluation can be communicated regarding pathology that was not visible in the image/video clips provided.

Thank you for this referral. If the clinical or image interpretation does not parallel your findings or if I can be of any further assistance please contact me.

Sebastian Schaub, Sebastian Schaub, DVM, Dr. med. vet. DipECVDI
sebast.schaub@gmail.com