SonoPath Teleradiology

EDUCATIONAL TELECONSULTATION SERVICES™

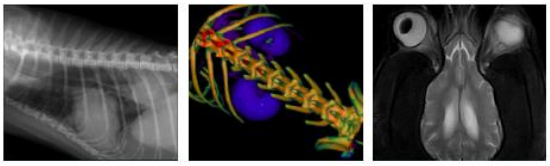

SonoPath.com
1-800-838-4268 info@sonopath.com

PATIENT

Coockie Faour

SPECIES

Feline

BREED

Domestic Shorthair

SEX

Female

AGE

2 Years

INTERPRETED BY

Sebastian Schaub, DVM
Dr. med. vet. DipECVDI

HOSPITAL NAME

Truscott Animal Hospital

REFERRING VET

Medhat Meawad

INVOICE

51622

DATE

4-19-22

PRESENTING CLINICAL SIGNS

Cat has one kitten delivery last sunday April 17 at 5am only one kitten and she has not cleaned herself and on physical exam there is lots of discharge coming out. Still eating and drinking well. Mild enlargement in mammary gland and enlarge in one of the uterine horn.

RADIOGRAPHIC STUDY OF THE ABDOMEN

Radiographs of the abdomen in three imaging planes are provided for review.

RADIOGRAPHIC FINDINGS

The surrounding bony structures are within normal limits.

The mammary glands are swollen and present a mild heterogeneous soft tissue opacity.

The serosal detail is maintained throughout the peritoneal and retroperitoneal space.

The liver is appropriate in position, size and presents uniform opacity.

The splenic head is in the anticipated position and within normal limits for size and opacity. The splenic body and tail are considered normal for position, size, shape and opacity.

Both kidneys are seen and present with normal size, shape, delineation and opacity. The urinary bladder is in its anticipated position. No radiopaque calculi are noted throughout the upper and lower urinary tract.

A prominent tubular structure is seen between the dorsal aspect of the urinary bladder and ventral to the descending colon, extending cranially into the abdominal cavity. The tubular structure is extending into the right &left lateral abdomen and presents a mild tortuous conformation.

The stomach is in its anticipated position and presents normal content.

The small intestinal loops are of even diameter and non-dilated, a small amount of gas is seen within the small intestinal loops and considered within normal limits.

The colon is seen in the expected position and presents with appropriate content.

RADIOGRAPHIC DIAGNOSIS

- Current state two days post-partum with prominent uterine horns
- Secondary hyperplasia of the mammary glands

INTERPRETATION OF THE FINDINGS & FURTHER RECOMMENDATIONS

The findings present a state post-partum with the uterus likely being in involution, there is no evidence of a retained fetus. However, secondary uterine infection or retained placenta is a consideration. Consider empirical management and if clinical signs persist, an ultrasound examination of the uterus appears beneficial.

SonoPath Teleradiology

EDUCATIONAL TELECONSULTATION SERVICES™

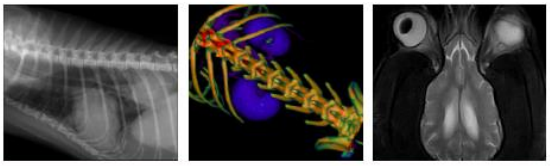

SonoPath.com
1-800-838-4268 info@sonopath.com

PATIENT

Coockie Faour

SPECIES

Feline

BREED

Domestic Shorthair

SEX

Female

AGE

2 Years

INTERPRETED BY

Sebastian Schaub, DVM
Dr. med. vet. DipECVDI

HOSPITAL NAME

Truscott Animal Hospital

REFERRING VET

Medhat Meawad

INVOICE

51622

DATE

4-19-22

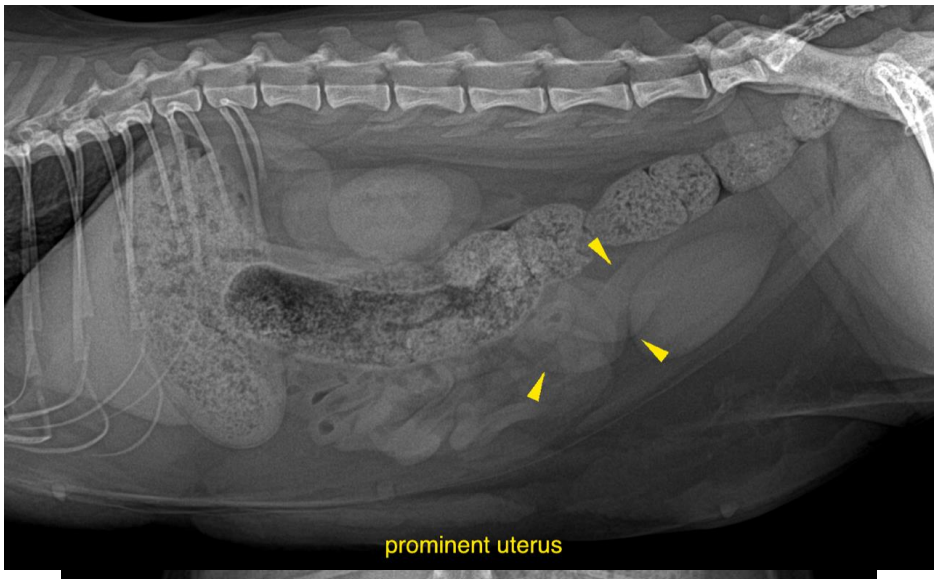

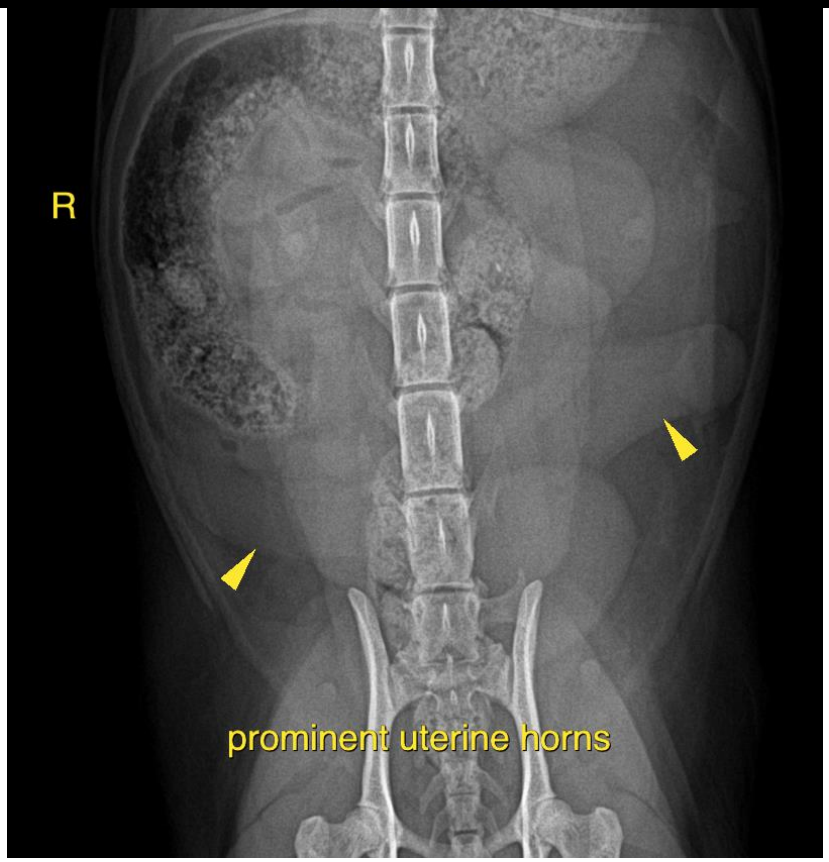

SonoPath Teleradiology

EDUCATIONAL TELECONSULTATION SERVICES™

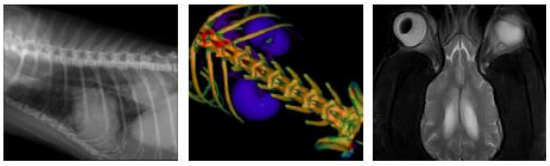

SonoPath.com
1-800-838-4268 info@sonopath.com

PATIENT

Coockie Faour

SPECIES

Feline

BREED

Domestic Shorthair

SEX

Female

AGE

2 Years

INTERPRETED BY

Sebastian Schaub, DVM
Dr. med. vet. DipECVDI

HOSPITAL NAME

Truscott Animal Hospital

REFERRING VET

Medhat Meawad

INVOICE

51622

DATE

4-19-22

The information and recommendations provided are based on the images presented by the referring veterinarian/sonographer. No evaluation can be communicated regarding pathology that was not visible in the image/video clips provided.

Thank you for this referral. If the clinical or image interpretation does not parallel your findings or if I can be of any further assistance please contact me.

Sebastian Schaub, Sebastian Schaub, DVM, Dr. med. vet. DipECVDI
sebast.schaub@gmail.com