



PATIENT

Aki Diyeva

PRESENTING CLINICAL SIGNS

LAMENESS ON THE LEFT HIND LEG HEART MURMUR 3-4/6 MAMMARY GLAND TUMOR
SWOLLEN LEFT STIFLE
Abnormal PE/Chem/CBC/UA Results: BW- WNL

SPECIES

Canine

RADIOGRAPHIC STUDY OF THE LEFT STIFLE JOINT

Radiographs of the left stifle joint in two orthogonal imaging planes are provided for review. Radiographs are provided in JPEG file format.

BREED

Maltese

RADIOGRAPHIC FINDINGS

The distal third of the left femur, including the femoral condyles, present with an ill-defined zone with permeative osteolytic lesions with multifocal destruction of the cortex. Mild immature periosteal new bone formation is seen along the distal left femur and in the proximal aspect elevation of the periosteum forming a Codman's triangle is seen. The left distal femur presents a moderate circumferential soft tissue swelling.

SEX

Female

RADIOGRAPHIC DIAGNOSIS

- Monostotic aggressive osteolytic lesion distal left femur

AGE

13

INTERPRETED BY

Sebastian Schaub, DVM
Dr. med. vet. DipECVDI

INTERPRETATION OF THE FINDINGS & FURTHER RECOMMENDATIONS

The findings are consistent with osseous neoplasia, given the large mammary mass, the odds for osseous metastasis of mammary carcinoma are considered high. Primary osseous neoplasia – such as osteosarcoma, chondrosarcoma, fibrosarcoma – is a consideration but appears less likely in this case.

HOSPITAL NAME

Kew Gardens Animal
Hospital

REFERRING VET

Dr. Sharkaway

INVOICE

51628

DATE

4-19-22



PATIENT

Aki Diyeva

SPECIES

Canine

BREED

Maltese

SEX

Female

AGE

13

INTERPRETED BY

Sebastian Schaub, DVM
Dr. med. vet. DipECVDI

HOSPITAL NAME

Kew Gardens Animal
Hospital

REFERRING VET

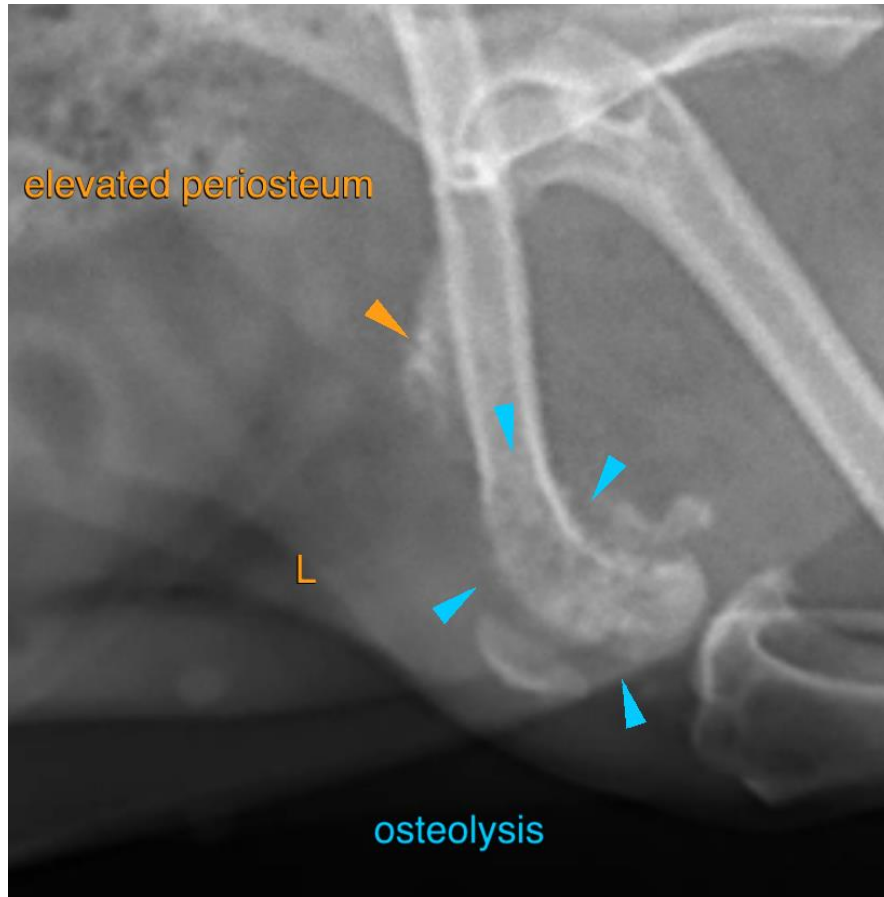
Dr. Sharkaway

INVOICE

51628

DATE

4-19-22



The information and recommendations provided are based on the images presented by the referring veterinarian/sonographer. No evaluation can be communicated regarding pathology that was not visible in the image/video clips provided.

Thank you for this referral. If the clinical or image interpretation does not parallel your findings or if I can be of any further assistance please contact me.

Sebastian Schaub, Sebastian Schaub, DVM, Dr. med. vet. DipECVDI
sebast.schaub@gmail.com