



PATIENT PRESENTING CLINICAL SIGNS

Lola Perdomo Hx of blood in the urine UA results free catch bacteria moderate cocci 9-40 HPF crystals 1+ ammonium phosphate 1-5 HPF phone call to o to advise on results recommend rads asap to r/o cystic calculi

SPECIES RADIOGRAPHIC STUDY OF THE THORAX & ABDOMEN

Canine A complete set of radiographs of the thorax & abdomen is provided for review.

RADIOGRAPHIC FINDINGS

BREED Thorax

Pug The thorax has a breed specific barrel chested conformation.

Multifocal spondylosis formation is seen along the thoracic & lumbar spine.

SEX The extrathoracic soft tissues present homogeneous without abnormalities.

FS The heart is of normal size and shape, there is no evidence of cardiac chamber or vascular enlargement. The pulmonary vasculature is within normal limits.

AGE The cranial mediastinum presents the expected soft tissue opacity. The mediastinal width is less than twice the width of the vertebral column at the same level.

6 The trachea is normal in diameter and presents the anticipated course. The luminal outline of the trachea is smooth.

INTERPRETED BY The bronchial tree presents with thin walls and tapers uniformly towards the periphery as expected.

Sebastian Schaub, DVM Dr. med. vet. DipECVDI The lung parenchyma presents the expected architecture and opacity; the intrapulmonary vascular branching is seen up to the third order lung vessels.

HOSPITAL NAME The diaphragm is well delineated with even surface and the expected mild cranial bulging of the diaphragmatic cupola.

Animal Paradise Hospital **Abdomen**

The surrounding bony structures are within normal limits. The periarticular bones of the coxofemoral joints present mild osteophyte new bone formation.

REFERRING VET No abnormalities of the extraabdominal soft tissues are noted. The abdominal wall is smooth and thin.

Dr. Hellwarth The serosal detail is maintained throughout the peritoneal and retroperitoneal space.

The liver is appropriate in position, size and presents uniform opacity.

INVOICE The splenic head is in the anticipated position and within normal limits for size and opacity. The splenic body and tail are considered normal for position, size, shape and opacity.

57837

Both kidneys are seen and present with normal size, shape, delineation and opacity. The urinary bladder is in its anticipated position. No radiopaque calculi are noted throughout the upper and lower urinary tract.

DATE

4-18-23

The stomach is in its anticipated position and contains foamy material and multiple mineral opaque osseous bodies in the pyloric region.

The small intestinal loops are of even diameter and non-dilated, a small amount of gas is seen within the



PATIENT small intestinal loops and considered within normal limits.

Lola Perdomo The colon is seen in the expected position and presents with appropriate content.

RADIOGRAPHIC DIAGNOSIS

- SPECIES**
- Multiple osseous bodies in stomach – likely due to fed diet
 - Degenerative osteoarthritis coxofemoral joints bilaterally
- CANINE**
- Spondylosis deformans

BREED INTERPRETATION OF THE FINDINGS & FURTHER RECOMMENDATIONS

PUG The radiographic study presents without evidence of radiopaque calculi throughout the urinary tract, however non-radiopaque calculi cannot be ruled out – struvite calculi are radiopaque. Ultrasound can be used to rule out non-radiopaque urinary calculi entirely.

SEX No additional clinically relevant pathologies are appreciated.

FS

AGE

6

INTERPRETED BY

Sebastian Schaub, DVM
Dr. med. vet. DipECVDI

HOSPITAL NAME

Animal Paradise
Hospital

REFERRING VET

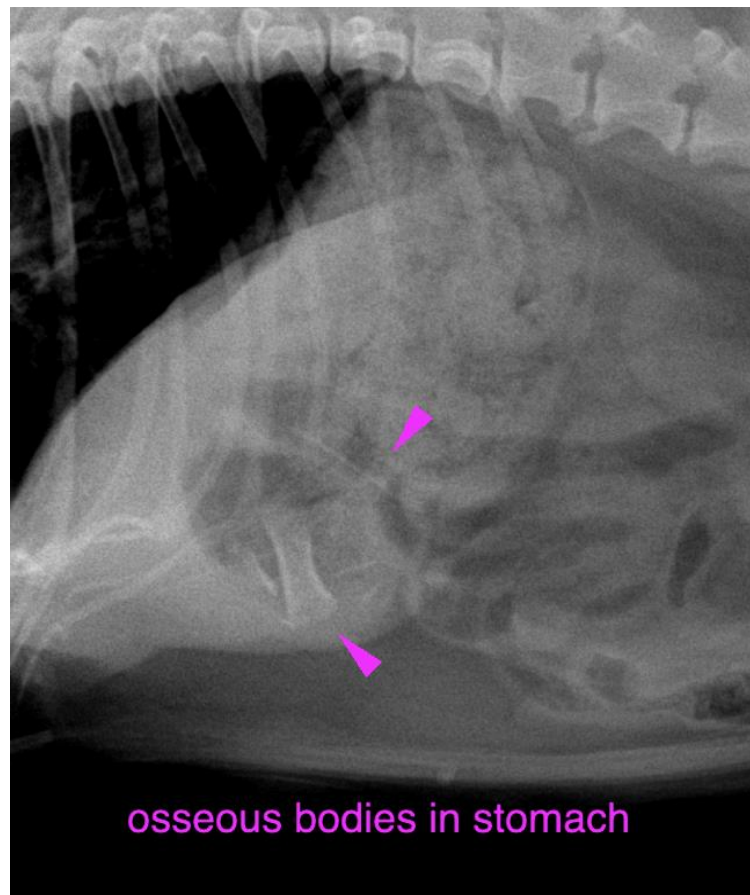
Dr. Hellwarth

INVOICE

57837

DATE

4-18-23





PATIENT

Lola Perdomo

SPECIES

Canine

The information and recommendations provided are based on the images presented by the referring veterinarian/sonographer. No evaluation can be communicated regarding pathology that was not visible in the image/video clips provided.

Thank you for this referral. If the clinical or image interpretation does not parallel your findings or if I can be of any further assistance please contact me.

BREED

Pug

Sebastian Schaub, Sebastian Schaub, DVM, Dr. med. vet. DipECVDI
sebast.schaub@gmail.com

SEX

FS

AGE

6

INTERPRETED BY

Sebastian Schaub, DVM
Dr. med. vet. DipECVDI

HOSPITAL NAME

Animal Paradise
Hospital

REFERRING VET

Dr. Hellwarth

INVOICE

57837

DATE

4-18-23