



PATIENT PRESENTING CLINICAL SIGNS

Cooper Martinez 03/21/22 lump noted on left side of neck. Needle aspirate and cytology performed (reactive lymphoid hyperplasia), culture (no growth observed). He was put on Zeniquin. 03/23/22 owner said swelling was spreading closer to the left ear. Sent home gabapentin, and rimadyl. The swelling has significantly reduced in size.

SPECIES Abnormal PE/Chem/CBC/UA Results: Cytology and culture results are attached for reference.

Canine

COMPUTED TOMOGRAPHY OF THE NECK

BREED A high resolution pre- and post-contrast CT study of the neck is provided for review.

Beagle Mix **COMPUTED TOMOGRAPHIC FINDINGS**

Both temporomandibular joints present congruent joint spaces with even subchondral bone surfaces and are considered within normal limits.

SEX

Neutered Male Both tympanic bullae are aerated, the mucosal lining is not seen, the bony wall is smooth and thin. The external ear canals are within normal limits.

AGE

6 Years The brain presents no deviation from normal anatomy and symmetry. The brain parenchyma is homogeneous and within normal limits for attenuation and distribution of contrast enhancement. The ventricular system is non-dilated and symmetric.

The submandibular and medial retropharyngeal lymph nodes are small and elongated with a normal short-to-long-axis-ratio is < 0.5, the attenuation and contrast enhancement pattern is uniform.

INTERPRETED BY

Sebastian Schaub, DVM
Dr. med. vet. DipECVDI

Level with the larynx/cranioventral aspect of the neck, a moderate subcutaneous soft tissue swelling with fat-stranding of the subcutaneous fat is appreciated.

HOSPITAL NAME

Mobile Pet Imaging

The remainder of the osseous and soft tissue structures of the neck are within normal limits.

COMPUTED TOMOGRAPHIC DIAGNOSIS

- Moderate edematous subcutaneous swelling cranioventral aspect of the neck – level with the larynx

REFERRING VET

Meaux

INTERPRETATION OF THE FINDINGS & FURTHER RECOMMENDATIONS

The subcutaneous edematous swelling ventral to the larynx – accentuated on the left sided – is not specific and an underlying cause can be specified. Rule out vasculitis, allergic reaction, sterile granulomatous dermatitis, mast cell tumor, infection. Complementing workup by biopsy might be beneficial.

INVOICE

51580

The regional lymph nodes are small and unremarkable.

DATE

4-18-22



PATIENT

Cooper Martinez

SPECIES

Canine

BREED

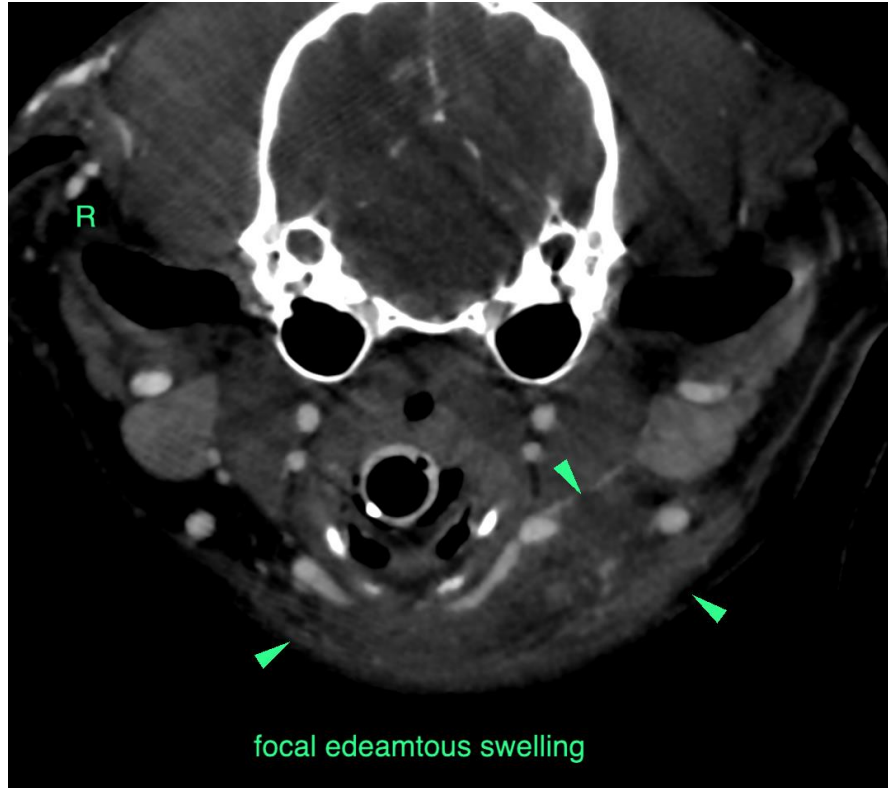
Beagle Mix

SEX

Neutered Male

AGE

6 Years



INTERPRETED BY

Sebastian Schaub, DVM
Dr. med. vet. DipECVDI

HOSPITAL NAME

Mobile Pet Imaging

REFERRING VET

Meaux

The information and recommendations provided are based on the images presented by the referring veterinarian/sonographer. No evaluation can be communicated regarding pathology that was not visible in the image/video clips provided.

Thank you for this referral. If the clinical or image interpretation does not parallel your findings or if I can be of any further assistance please contact me.

Sebastian Schaub, Sebastian Schaub, DVM, Dr. med. vet. DipECVDI
sebast.schaub@gmail.com

INVOICE

51580

DATE

4-18-22