



PATIENT PRESENTING CLINICAL SIGNS

Boomer Hatfield Right sided epistaxis (once) with significant sneezing and head shaking since that time. No nasal discharge noted. Plant awn removed from the right nasal cavity. Concurrent increase ALP (4000/L) with only mild increase ALT (276 U/L) and normal GGT, cholesterol, and PT, PTT. No clinical signs of polyuria, polydipsia, polyphagia, or hair loss. No bone pain noted on physical examination. Abnormal PE/Chem/CBC/UA Results: Increase ALP, ALT. normal PLT, PT, PTT.

Canine

COMPUTED TOMOGRAPHY OF THE SKULL

A high resolution pre- and post-contrast CT study of the skull is provided for review.

BREED

COMPUTED TOMOGRAPHIC FINDINGS

Boxer Mix

The tooth elements 305, 306, 311, 405, 506 and 411 are absent.

SEX

In the rostral aspect of the right nasal cavity, a fusiform shaped consolidated area is visible. The remainder of the nasal cavity presents the expected aerated spaces between thin & even conchae and turbinates with smooth mucosal lining.

Male Neutered

Both temporomandibular joints present congruent joint spaces with even subchondral bone surfaces and are considered within normal limits.

AGE

Both tympanic bullae are aerated, the mucosal lining is not seen, the bony wall is smooth and thin. The external ear canals are within normal limits.

11

INTERPRETED BY

The brain presents no deviation from normal anatomy and symmetry. The brain parenchyma is homogeneous and within normal limits for attenuation and distribution of contrast enhancement. The ventricular system is non-dilated and symmetric.

Sebastian Schaub, DVM
Dr. med. vet. DipECVDI

The submandibular and medial retropharyngeal lymph nodes are small and elongated with a normal short-to-long-axis-ratio is < 0.5, the attenuation and contrast enhancement pattern is uniform.

HOSPITAL NAME

COMPUTED TOMOGRAPHIC DIAGNOSIS

CARE Surgery Center

- Focal area of nasal consolidation rostral aspect right nasal cavity
- Absent triadan 305, 306, 311, 405, 506 and 411

REFERRING VET

INTERPRETATION OF THE FINDINGS & FURTHER RECOMMENDATIONS

Dr. Radlinsky

Focal consolidated area rostral segment right nasal cavity - the finding in combination with the presenting clinical signs is suggestive for nasal foreign body. Regarding the history a plant awn has already been removed from the right nasal cavity. The CT study is negative for biologically aggressive nasal disease.

INVOICE

57834

DATE

4-17-23



PATIENT

Boomer Hatfield

SPECIES

Canine

BREED

Boxer Mix

SEX

Male Neutered

AGE

11

INTERPRETED BY

Sebastian Schaub, DVM
Dr. med. vet. DipECVDI

HOSPITAL NAME

CARE Surgery Center

REFERRING VET

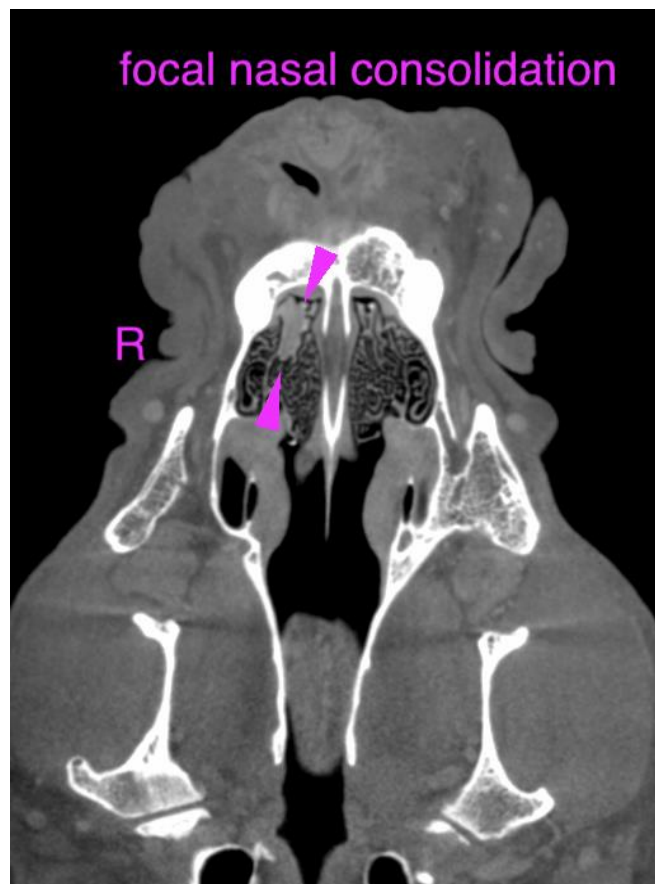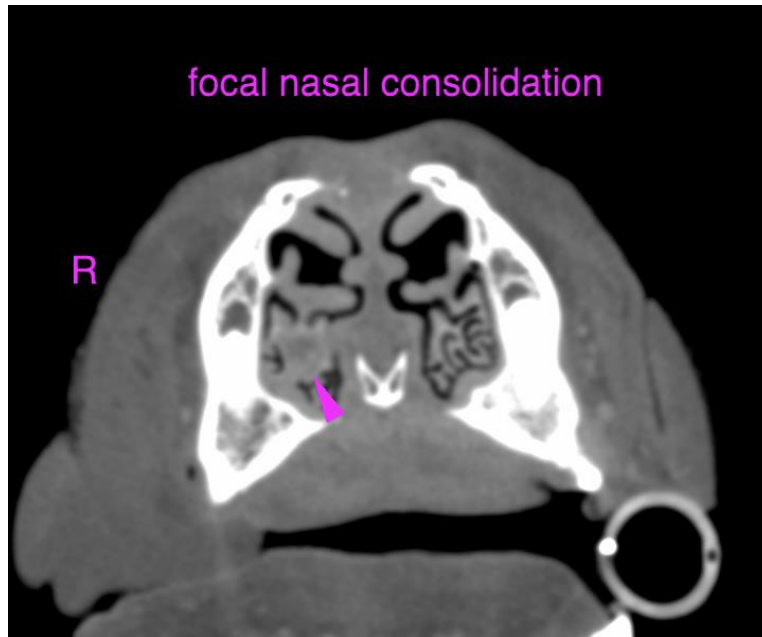
Dr. Radlinsky

INVOICE

57834

DATE

4-17-23





PATIENT

Boomer Hatfield

SPECIES

Canine

The information and recommendations provided are based on the images presented by the referring veterinarian/sonographer. No evaluation can be communicated regarding pathology that was not visible in the image/video clips provided.

BREED

Boxer Mix

Thank you for this referral. If the clinical or image interpretation does not parallel your findings or if I can be of any further assistance please contact me.

Sebastian Schaub, Sebastian Schaub, DVM, Dr. med. vet. DipECVDI
sebast.schaub@gmail.com

SEX

Male Neutered

AGE

11

INTERPRETED BY

Sebastian Schaub, DVM
Dr. med. vet. DipECVDI

HOSPITAL NAME

CARE Surgery Center

REFERRING VET

Dr. Radlinsky

INVOICE

57834

DATE

4-17-23