



PATIENT

Osita Odette

PRESENTING CLINICAL SIGNS

Firm lump on toe. Growing.
Abnormal PE/Chem/CBC/UA Results: Not painful on exam. Bony protrusion P3 of RH 2nd digit. r/o nail involvement, neoplastic etc.

SPECIES

Canine

RADIOGRAPHIC STUDY OF THE HIND PAWS

Radiographs of the digits of the right hind paw are provided in two imaging planes.

BREED

Mixed Breed

RADIOGRAPHIC FINDINGS

The proximal phalanx of the second digit of the right hind limb presents with an eccentric growing cauliflower like mineralizing mass. There appears to be moth eaten osteolysis of the associated cortex of the proximal phalanx of the second digit.

SEX

FS

The remainder of the osseous and soft tissue structures of the digits of the right hind paw are within normal limits.

AGE

12 Years

RADIOGRAPHIC DIAGNOSIS

- Monostotic semiaggressive osteoproliferative mass proximal phalanx second digit right hind limb

INTERPRETED BY

Sebastian Schaub, DVM
Dr. med. vet. DipECVDI

INTERPRETATION OF THE FINDINGS & FURTHER RECOMMENDATIONS

The findings are consistent with the history of an osteoproliferative mass, differentials include osteochondroma, chondrosarcoma, (periosteal) osteosarcoma, squamous cell carcinoma, other. Amputation of the respective digit is considered as the therapy of choice.

HOSPITAL NAME

Pinebrook Animal
Hospital

Consider full tumor staging.

REFERRING VET

Dr. Britt Dubil

INVOICE

51557

DATE

4-16-22



PATIENT

Osita Odette

SPECIES

Canine

BREED

Mixed Breed

SEX

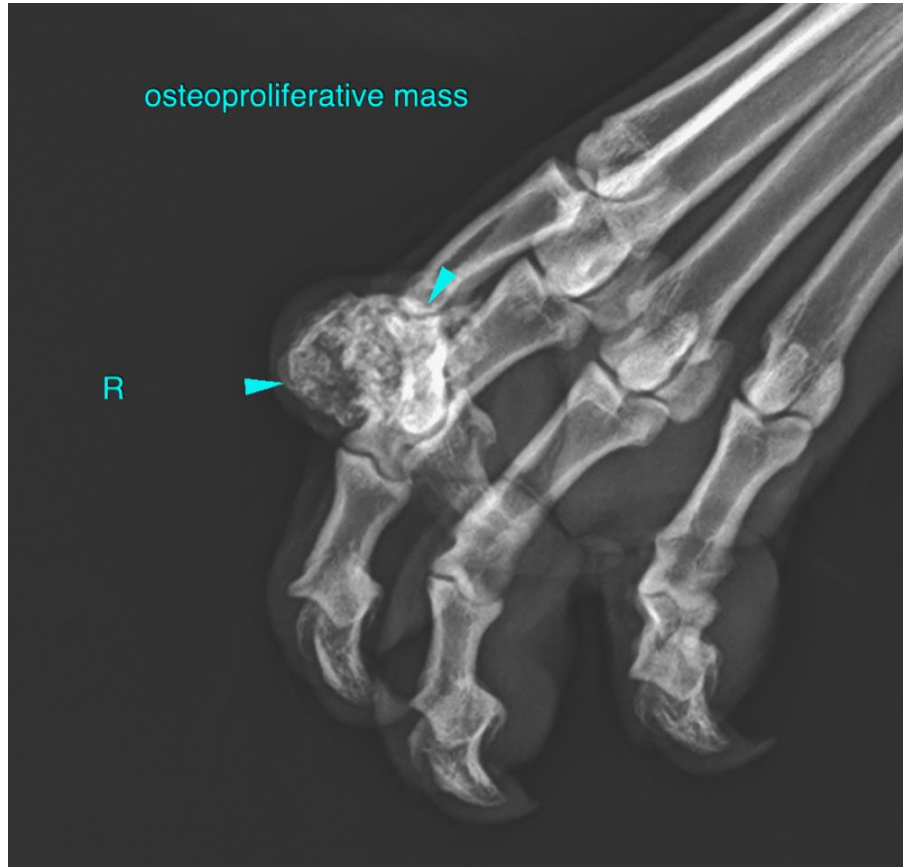
FS

AGE

12 Years

INTERPRETED BY

Sebastian Schaub, DVM
Dr. med. vet. DipECVDI



HOSPITAL NAME

Pinebrook Animal
Hospital

REFERRING VET

Dr. Britt Dubil

INVOICE

51557

DATE

4-16-22

The information and recommendations provided are based on the images presented by the referring veterinarian/sonographer. No evaluation can be communicated regarding pathology that was not visible in the image/video clips provided.

Thank you for this referral. If the clinical or image interpretation does not parallel your findings or if I can be of any further assistance please contact me.

Sebastian Schaub, Sebastian Schaub, DVM, Dr. med. vet. DipECVDI
sebast.schaub@gmail.com