



PATIENT

Diamond Yogurtcu

PRESENTING CLINICAL SIGNS

S: P is here to check on rear left leg P has a broken nail. O would like a nail trim ok e/d/u/d no c/s/v/d O: lame 4/5 LH, BAR, m.m-pink, CRT<2sec, EENT, teeth- severe tartar, H/L, Abdo, U/G, skin and coat- alopecia on tail, M/S- LH positive drawer movement A: CCL injury or rupture

SPECIES

Canine

RADIOGRAPHIC STUDY OF THE PELVIS & LEFT STIFLE JOINT

A complete set of radiographs of the pelvis and the left stifle joint is provided for review.

BREED

Pit Bull

RADIOGRAPHIC FINDINGS

The osseous and surrounding soft tissue structures of the pelvis are within normal limits. Both coxofemoral joints present smooth osseous margins and congruent joint spaces.

SEX

FS

The volume of the soft tissue shadow of the left thigh musculature is moderately decreased.

The periarticular bones of the left stifle joint present moderate osteophyte new bone formation. A moderate intracapsular soft tissue swelling of the left stifle joint is appreciated.

AGE

9 Years

RADIOGRAPHIC DIAGNOSIS

- Moderate articular swelling left stifle joint
- Mild degenerative osteoarthritis left stifle joint
- Disuse atrophy left thigh musculature
- Normal pelvis

INTERPRETED BY

Sebastian Schaub, DVM
Dr. med. vet. DipECVDI

INTERPRETATION OF THE FINDINGS & FURTHER RECOMMENDATIONS

The radiographic study is consistent with mild chronic degenerative osteoarthritis with concomitant joint effusion of the left stifle joint. The most-likely underlying cause is (partial) rupture of the cranial cruciate ligament with or without meniscal disease.

HOSPITAL NAME

Animal Paradise
Hospital

A positive drawer sign or tibial compression test under general anesthesia can be used to confirm the diagnosis.

REFERRING VET

Dr. Elshafie

INVOICE

51561

DATE

4-16-22



PATIENT

Diamond Yogurtcu

SPECIES

Canine

BREED

Pit Bull

SEX

FS

AGE

9 Years

INTERPRETED BY

Sebastian Schaub, DVM
Dr. med. vet. DipECVDI

HOSPITAL NAME

Animal Paradise
Hospital

REFERRING VET

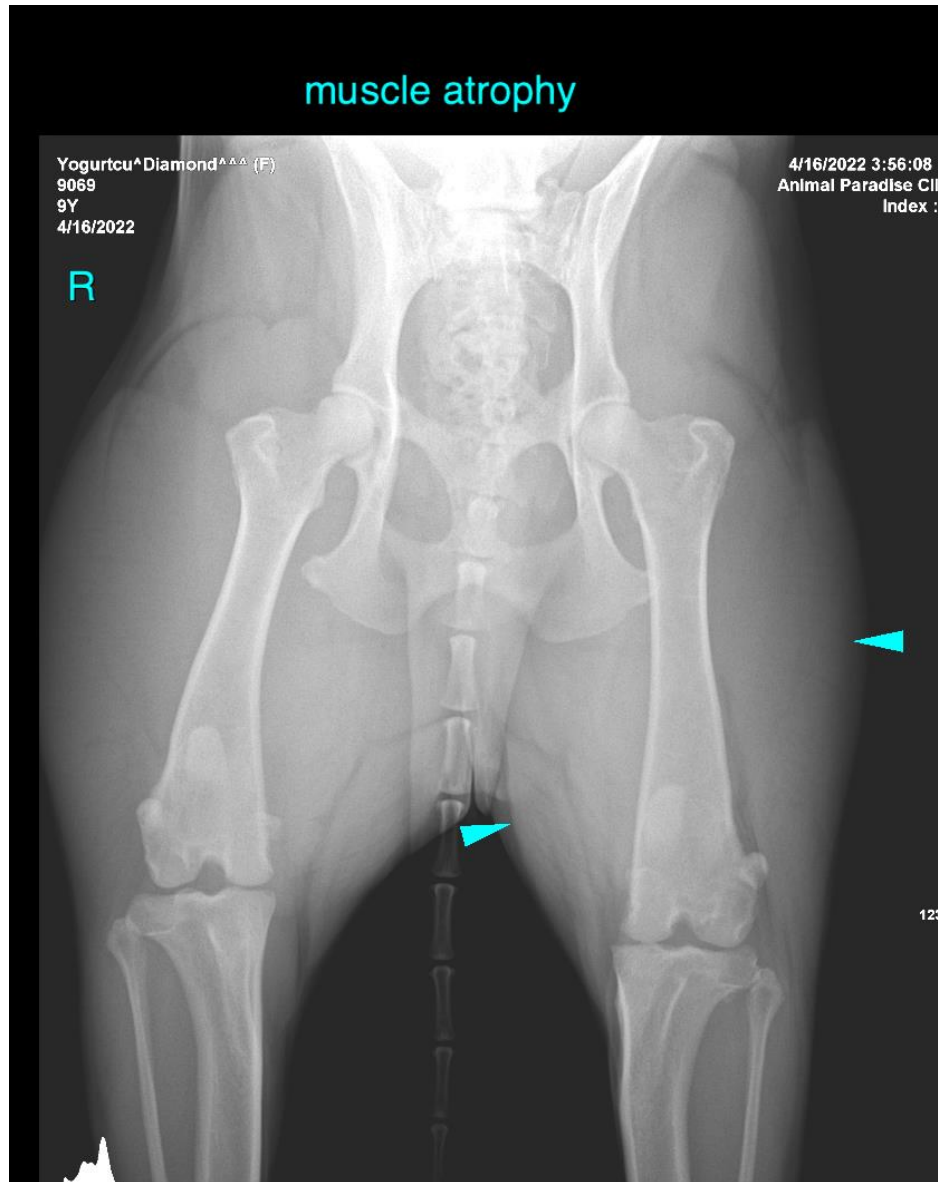
Dr. Elshafie

INVOICE

51561

DATE

4-16-22





PATIENT

Diamond Yogurtcu

SPECIES

Canine

BREED

Pit Bull

SEX

FS

AGE

9 Years

INTERPRETED BY

Sebastian Schaub, DVM
Dr. med. vet. DipECVDI

HOSPITAL NAME

Animal Paradise
Hospital

REFERRING VET

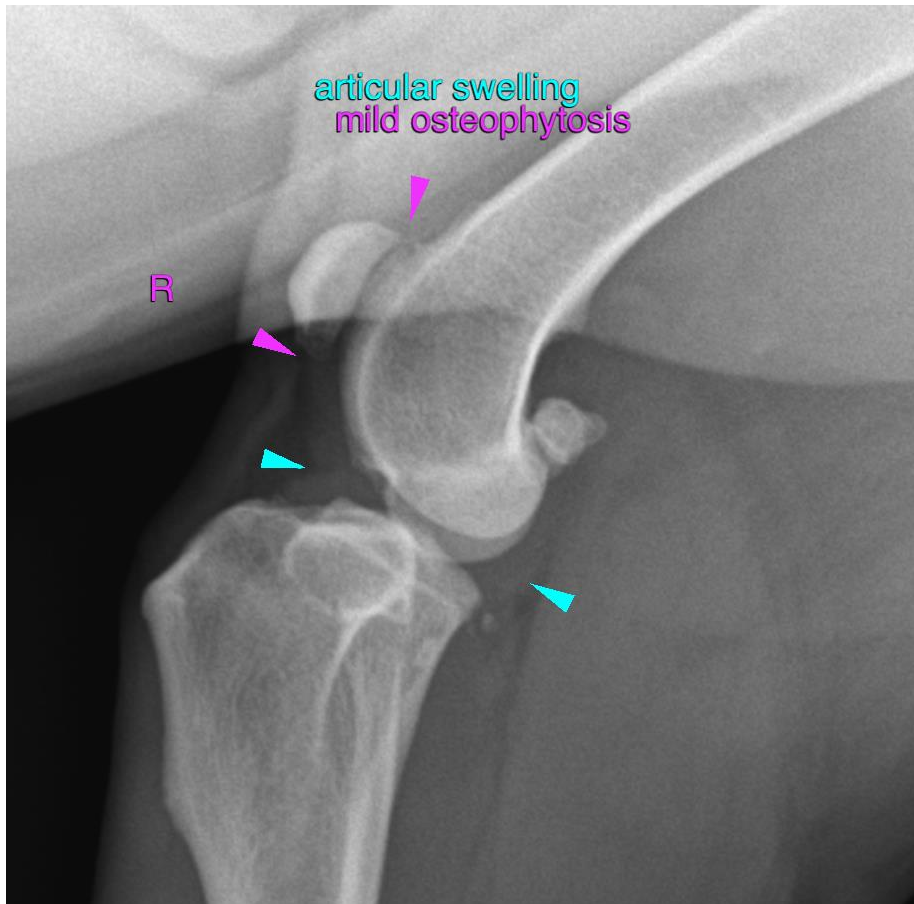
Dr. Elshafie

INVOICE

51561

DATE

4-16-22



The information and recommendations provided are based on the images presented by the referring veterinarian/sonographer. No evaluation can be communicated regarding pathology that was not visible in the image/video clips provided.

Thank you for this referral. If the clinical or image interpretation does not parallel your findings or if I can be of any further assistance please contact me.

Sebastian Schaub, Sebastian Schaub, DVM, Dr. med. vet. DipECVDI
sebast.schaub@gmail.com