



**PATIENT**

Boris the Animal Neff

**SPECIES**

Canine

**BREED**

Pit Bull

**SEX**

NM

**AGE**

6 Years, 9 Months

**INTERPRETED BY**

Sebastian Schaub, DVM  
Dr. med. vet. DipECVDI

**HOSPITAL NAME**

DPC Veterinary  
Hospital

**REFERRING VET**

Dr. Feldt

**INVOICE**

51562

**DATE**

4-16-22

**PRESENTING CLINICAL SIGNS**

Reason for Visit: LIMPING FROM RIGHT REAR History: LIMPING FROM 3-4 WEEKS, BUT SEEMED TO REALLY BOTHER HIM 2 DAYS AGO, NOT WANTING TO PUT ANY WEIGHT Abnormal PE/Chem/CBC/UA Results: Hydration: N Mentation: happy dog until you try to restrain then gets very aggressive EENT: N Oral Cavity: N Lymph Nodes: N Skin: N CV/Respiratory: N Abd/GI: N Uro/Perineum: N Musculoskeletal: Toe touching right rear, positive drawer right stifle, no meniscal click Neurological: N

**RADIOGRAPHIC STUDY OF THE STIFLE JOINTS**

Radiographs of the stifle joints in two imaging planes are provided for review.

**RADIOGRAPHIC FINDINGS**

The periarticular bones of the right stifle joint present mild osteophyte new bone formation. The right stifle joint presents moderate intracapsular soft tissue swelling. Mild cranial subluxation of the tibia, relative to the tibial eminence is noted.

The left stifle joint presents smooth osseous margins and without evidence of intracapsular soft tissues welling.

**RADIOGRAPHIC DIAGNOSIS**

- Mild degenerative osteoarthritis right stifle joint
- Moderate articular swelling right stifle joint
- Mild cranial subluxation right tibia
- Normal left stifle joint

**INTERPRETATION OF THE FINDINGS & FURTHER RECOMMENDATIONS**

The radiographic study is consistent with mild chronic degenerative osteoarthritis with concomitant joint effusion of the right stifle joints. The cranial subluxation of the right tibia is supporting the diagnosis of failure of the cranial cruciate ligament ± meniscal pathology.

The clinically appreciated positive drawer sign is supporting the diagnosis as well and surgical management of cranial cruciate ligament failure is considered beneficial.



**PATIENT**

Boris the Animal Neff

**SPECIES**

Canine

**BREED**

Pit Bull

**SEX**

NM

**AGE**

6 Years, 9 Months

**INTERPRETED BY**

Sebastian Schaub, DVM  
Dr. med. vet. DipECVDI

**HOSPITAL NAME**

DPC Veterinary  
Hospital

**REFERRING VET**

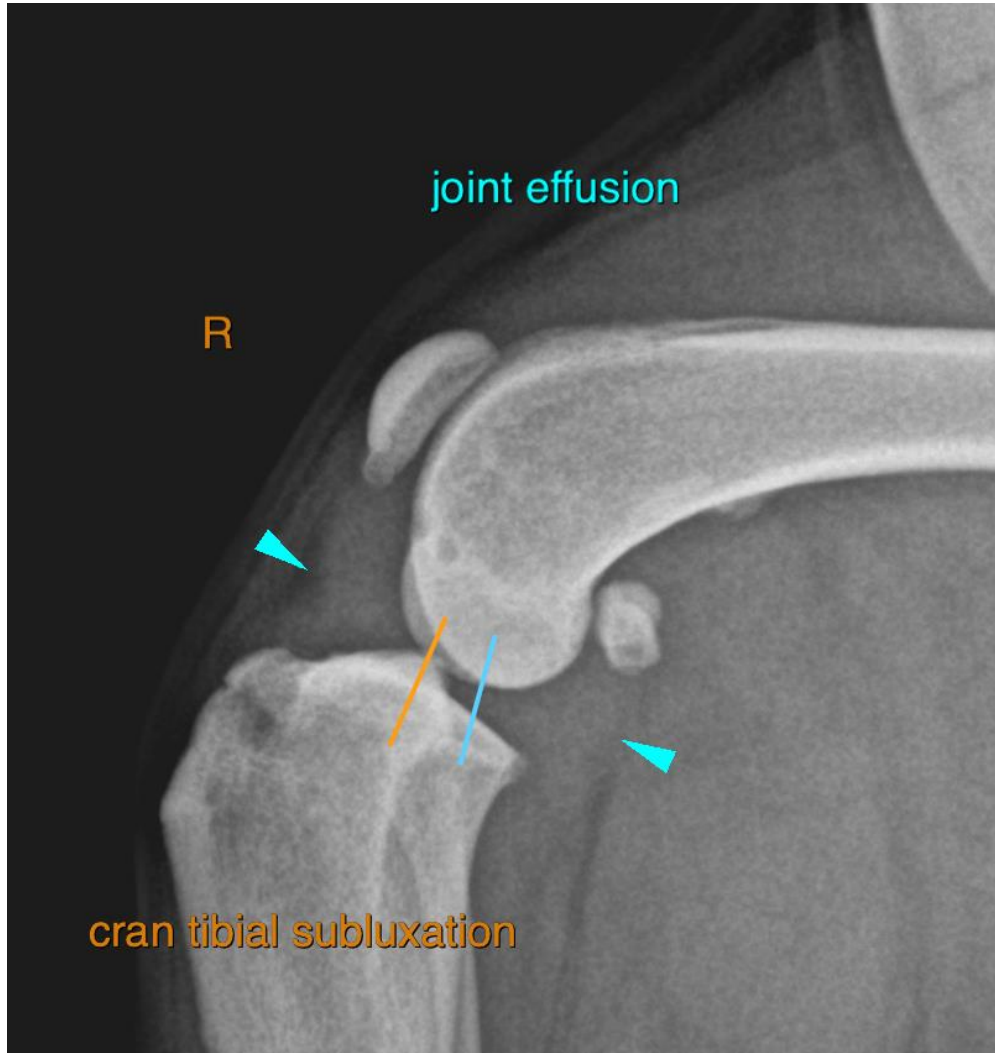
Dr. Feldt

**INVOICE**

51562

**DATE**

4-16-22



The information and recommendations provided are based on the images presented by the referring veterinarian/sonographer. No evaluation can be communicated regarding pathology that was not visible in the image/video clips provided.

Thank you for this referral. If the clinical or image interpretation does not parallel your findings or if I can be of any further assistance please contact me.

**Sebastian Schaub**, Sebastian Schaub, DVM, Dr. med. vet. DipECVDI  
sebast.schaub@gmail.com