



PATIENT

Toby Hoydick

SPECIES

Canine

BREED

Border Collie Mix

SEX

NM

AGE

11Y, 5M

WEIGHT

50lbs

INTERPRETED BY

Sebastian Schaub, DVM
Dr. med. vet.
DipECVDD

IMAGING PERFORMED BY

GC/DD

HOSPITAL NAME

The Pet Hospital of
Stratford

REFERRING VET

Dr. Claudia Giuliani,
DVM

INVOICE

74615

DATE

4-15-26

PRESENTING CLINICAL SIGNS

Toby presents for bite of unknown origin that occurred Sunday night. Owner states that he was outside and they heard a ruckus - went to check and he had an animal in his mouth (unsure of what kind of animal. Did not take him to ER at that moment. His R ear and his neck have been significantly swollen and he has been lethargic. 104 temp today.

RADIOGRAPHIC STUDY OF THE NECK

Radiographs of the neck in two orthogonal image planes are provided for review.

RADIOGRAPHIC FINDINGS

The subcutaneous tissue in the submandibular region is mild to moderately swollen and presents moderate soft tissue striation.

The subcutaneous tissue along the right lateral aspect of the neck, presents a diffuse significant soft tissue swelling and soft tissue striation of the subcutaneous fat. The subcutaneous swelling is extending cranially up to the level of the right ear.

The trachea is normal in diameter and presents the anticipated course. The luminal outline of the trachea is smooth.

The cranial cervical esophageal segment is mildly distended by gas.

RADIOGRAPHIC DIAGNOSIS

- Subcutaneous cellulitis right lateral aspect of the neck and region of the right ear

INTERPRETATION OF THE FINDINGS & FURTHER RECOMMENDATIONS

The radiographic changes are fitting the history of subcutaneous swelling - possibly due to preceding bite injury - the differential is septic cellulitis. Potentials can include hematoma, allergic/toxic edematous swelling or paraneoplastic origin (e.g. mast cell tumor). Workup may be complemented by an ultrasound examination of the swelling to screen for fluid pockets that may warrant surgical drainage.



PATIENT

Toby Hoydick

SPECIES

Canine

BREED

Border Collie Mix

SEX

NM

AGE

11Y, 5M

WEIGHT

50lbs

INTERPRETED BY

Sebastian Schaub, DVM
Dr. med. vet.
DipECVDI

IMAGING PERFORMED BY

GC/DD

HOSPITAL NAME

The Pet Hospital of
Stratford

REFERRING VET

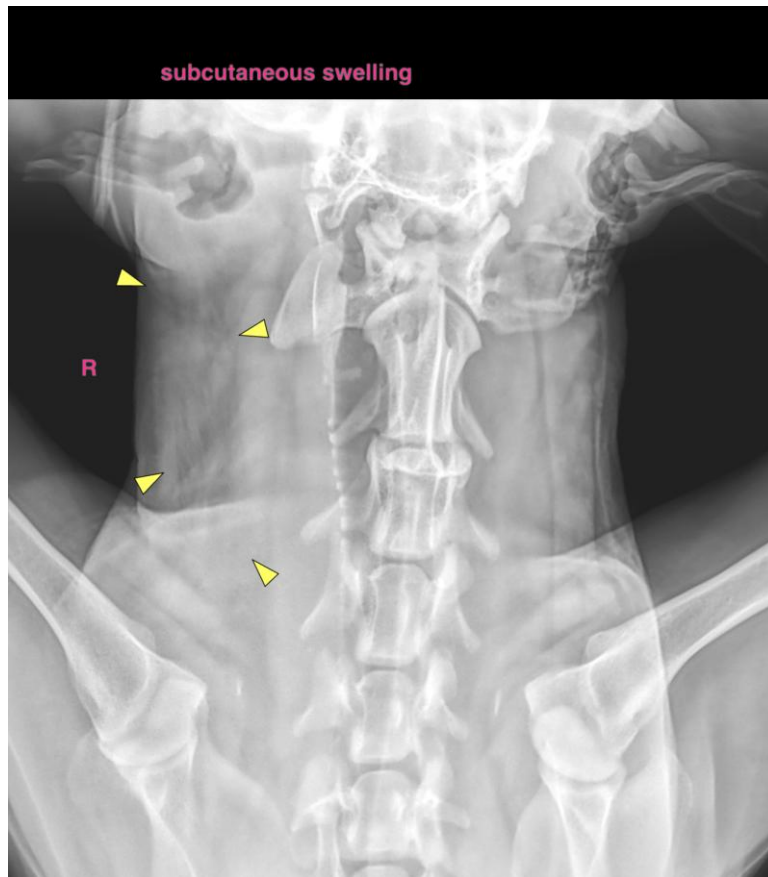
Dr. Claudia Giuliani,
DVM

INVOICE

74615

DATE

4-15-26



The information and recommendations provided are based on the images presented by the referring veterinarian/sonographer. No evaluation can be communicated regarding pathology that was not visible in the image/video clips provided.

Thank you for this referral. If the clinical or image interpretation does not parallel your findings or if I can be of any further assistance please contact me.

Sebastian Schaub, Sebastian Schaub, DVM, Dr. med. vet. DipECVDI
info@sonopath.com