



## PATIENT

Malcolm Wilson

## SPECIES

Canine

## BREED

Mix

## SEX

MN

## AGE

9

## WEIGHT

30kg

## INTERPRETED BY

Sebastian Schaub, DVM  
Dr. med. vet.  
DipECVDI

## IMAGING PERFORMED BY

Dr. Runde

## HOSPITAL NAME

Northeast Veterinary  
Referral Hospital

## REFERRING VET

Dr. Runde

## INVOICE

74616

## DATE

4-15-26

## PRESENTING CLINICAL SIGNS

presented for right epistaxis  
Abnormal PE/Chem/CBC/UA Results: normal

## COMPUTED TOMOGRAPHY OF THE SKULL & THORAX

A high resolution pre- and post-contrast CT study of the skull and thorax are provided for review.

## COMPUTED TOMOGRAPHIC FINDINGS

### Skull

Triadan 302 and 303 are absent. The tip of the crown of triadan 404 is absent, exposing the pulp cavity to the dental surface. Gas is appreciated in the pulp cavity of triadan 404.

The caudal half of the right nasal cavity is obliterated by uniform soft tissue attenuating and contrast enhancing material. Destruction of the associated nasal conchal structures is seen.

Both temporomandibular joints present congruent joint spaces with even subchondral bone surfaces and are considered within normal limits.

Both tympanic bullae are aerated, the mucosal lining is not seen, the bony wall is smooth and thin. The external ear canals are within normal limits.

The brain presents no deviation from normal anatomy and symmetry. The brain parenchyma is homogeneous and within normal limits for attenuation and distribution of contrast enhancement. The ventricular system is non-dilated and symmetric.

In the parenchyma of the mandibular salivary gland bilaterally, well-defined, roundish parenchymal filling defects are seen; measuring up to 4 mm in diameter.

The submandibular and medial retropharyngeal lymph nodes are small and elongated with a normal short-to-long-axis-ratio is < 0.5, the attenuation and contrast enhancement pattern is uniform.

### Thorax

The bony and surrounding soft tissue structures are within normal limits.

The sternal, cranial mediastinal and tracheobronchial lymph nodes are small elongated with a normal short-to-long-axis-ratio is < 0.5, the attenuation and contrast enhancement pattern is uniform and considered within normal limits. The right frontal sinus is filled with fluid attenuating material.

The pulmonary arteries are generalized dilated, have a mild tortuous course and present multifocal variable degree of intraluminal mineralization. The bronchial segments in the caudodorsal aspects of the caudal lung lobes are surrounded by a mesh of small tortuous vessels.

The bronchial tree presents with regular branching and tapers uniformly towards the periphery as expected, the bronchial walls are thin and smooth. The bronchus-to-artery ratio is within normal limits.

The lung parenchyma presents the expected architecture and attenuation behavior.

Small incidental gas pockets are seen within the esophageal lumen; there is no evidence of abnormal dilation.

## COMPUTED TOMOGRAPHIC DIAGNOSIS

- Right nasal soft tissue mass



## PATIENT

Malcolm Wilson

## SPECIES

Canine

## BREED

Mix

## SEX

MN

## AGE

9

## WEIGHT

30kg

## INTERPRETED BY

Sebastian Schaub, DVM  
Dr. med. vet.  
DipECVDP

## IMAGING PERFORMED BY

Dr. Runde

## HOSPITAL NAME

Northeast Veterinary  
Referral Hospital

## REFERRING VET

Dr. Runde

## INVOICE

74616

## DATE

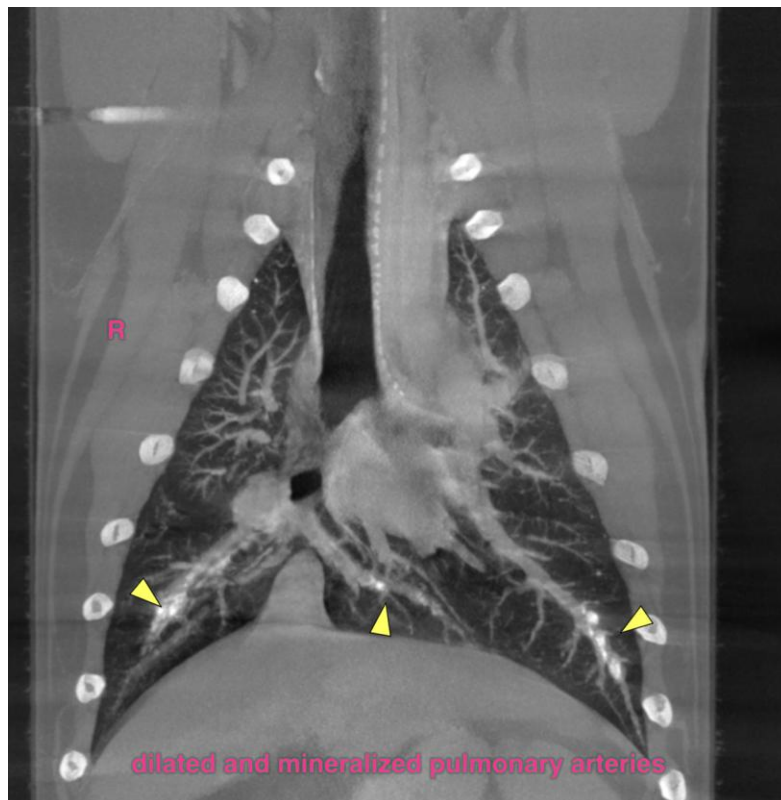
4-15-26

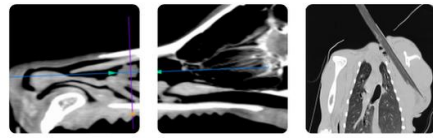
- Secondary obstructive sinusitis right frontal sinus
- Dilated pulmonary and tortuous pulmonary arteries – with segmental vascular mesh surrounding the bronchial walls – and multifocal intraluminal dystrophic mineralization
- Incidental small intraparenchymal cysts salivary gland bilaterally
- No evidence of pulmonary metastatic disease

## INTERPRETATION OF THE FINDINGS & FURTHER RECOMMENDATIONS

The right nasal soft tissue mass is consistent with primary nasal soft tissue neoplasia. Differentials include adenocarcinoma, squamous cell carcinoma lymphosarcoma, other. Rhinoscopy including biopsy can be performed for specification. The Adam tumor stage is 1.

The changes of the pulmonary arteries are likely a sequela to preceding or ongoing parasitic infection, such as *Dirofilaria immitis*. Testing for potential infection following the guidelines of the “American Heartworm Society” <https://www.heartwormsociety.org> may be beneficial.





## PATIENT

Malcolm Wilson

## SPECIES

Canine

## BREED

Mix

## SEX

MN

## AGE

9

## WEIGHT

30kg

## INTERPRETED BY

Sebastian Schaub, DVM  
Dr. med. vet.  
DipECVDI

## IMAGING PERFORMED BY

Dr. Runde

## HOSPITAL NAME

Northeast Veterinary  
Referral Hospital

## REFERRING VET

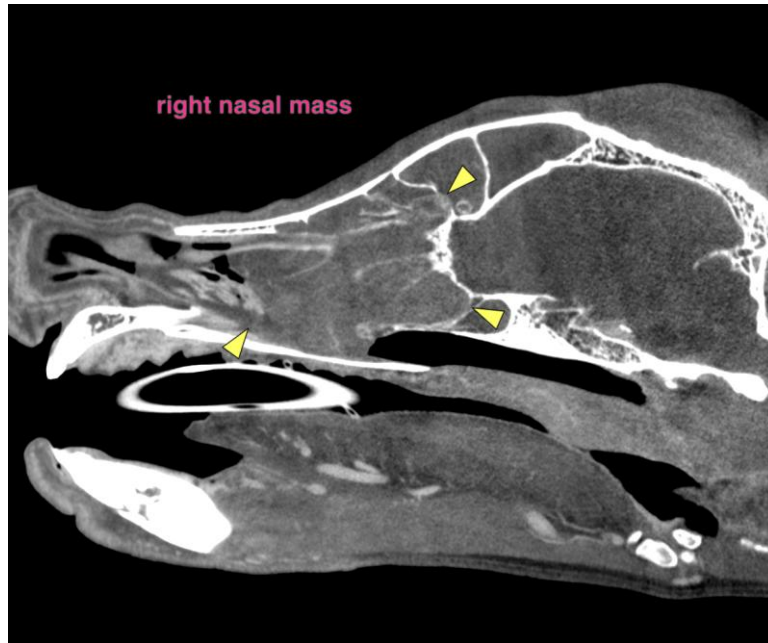
Dr. Runde

## INVOICE

74616

## DATE

4-15-26



The information and recommendations provided are based on the images presented by the referring veterinarian/sonographer. No evaluation can be communicated regarding pathology that was not visible in the image/video clips provided.

Thank you for this referral. If the clinical or image interpretation does not parallel your findings or if I can be of any further assistance please contact me.

**Sebastian Schaub**, Sebastian Schaub, DVM, Dr. med. vet. DipECVDI  
[info@sonopath.com](mailto:info@sonopath.com)